




# Vascular Liver Disorders, Portal Vein Thrombosis, and Procedural Bleeding in Patients With Liver Disease: 2020 Practice Guidance by the American Association for the Study of Liver Diseases

Patrick G. Northup <sup>1</sup>, Juan Carlos Garcia-Pagan <sup>2-4</sup>, Guadalupe Garcia-Tsao,<sup>5,6</sup> Nicolas M. Intagliata,<sup>1</sup> Riccardo A. Superina,<sup>7</sup> Lara N. Roberts,<sup>8</sup> Ton Lisman <sup>9</sup>, and Dominique C. Valla<sup>10,11</sup>

## New Features and Changes From the Previous American Association for the Study of Liver Diseases Guidelines

- An overview of the current understanding of bleeding and thrombosis in cirrhosis.
- An evidence-based justification for bleeding risk assessment in patients with cirrhosis before invasive procedures, including current concepts in preprocedural testing and laboratory analysis and their role in predicting bleeding complications.
- An outline of established and recently identified risk factors for venous thrombosis in the portal and hepatic venous systems in both patients with and without cirrhosis along with thrombophilia testing recommendations.
- A review of the strengths and weaknesses of the various classification systems for portal vein thrombosis and a proposal for standard nomenclature regarding characterization of portal vein thrombosis location, time course, and progression.
- A comprehensive review of procedural and medical therapies for treatment of portal vein thrombosis including the use of direct oral anticoagulants.
- A step-by-step treatment and surveillance algorithm for portal vein thrombosis in patients with cirrhosis.
- Updated diagnostic, treatment, and management recommendations for sinusoidal obstruction syndrome, hereditary hemorrhagic telangiectasia, and hepatic vein thrombosis.

*Abbreviations:* AASLD, American Association for the Study of Liver Diseases; ACLF, acute-on-chronic liver failure; AKI, acute kidney injury; aPTT, activated partial thromboplastin time; BCS, Budd-Chiari syndrome; CTP, Child-Turcotte-Pugh; DDAVP, 1-deamino-8-D-arginine vasopressin; DIPS, direct intrahepatic portosystemic shunt; DOAC, direct oral anticoagulant; EACA, epsilon-aminocaproic acid; EHPVO, extrahepatic portal vein obstruction; EVL, endoscopic variceal ligation; FDA, U.S. Food and Drug Administration; FFP, fresh frozen plasma; HA, hepatic artery; HAA, hepatic artery aneurysm; HHT, hereditary hemorrhagic telangiectasia; HV, hepatic vein; HVT, hepatic vein thrombosis; INCPH, idiopathic noncirrhotic portal hypertension; INR, international normalized ratio; IVC, inferior vena cava; LMWH, low-molecular-weight heparin; LT, liver transplantation; LVM, liver vascular malformation; PSVD, portosinusoidal vascular disease; PT, prothrombin time; PV, portal vein; PVR, portal vein recanalization; PVT, portal vein thrombosis; ROTEM, rotational thromboelastometry; SAA, splenic artery aneurysm; SOS, sinusoidal obstruction syndrome; TEG, thromboelastography; TIPS, transjugular intrahepatic portosystemic shunt; TIPS-PVR, transjugular intrahepatic portosystemic shunt–portal vein recanalization; tPA, tissue plasminogen activator; UFH, unfractionated heparin; VKA, vitamin K antagonist; VTE, venous thromboembolism; VWF, von Willebrand factor.

Received November 16, 2020; accepted November 16, 2020.

Funding for the development of this Practice Guidance was provided by the American Association for the Study of Liver Diseases.

© 2020 by the American Association for the Study of Liver Diseases.

- Classification and management recommendations for idiopathic noncirrhotic portal hypertension and the portosinusoidal vascular disorders.
- Surveillance and evaluation recommendations for hepatic and splenic artery aneurysms.
- A review of the management issues in vascular liver disorders specific to children and guidance on early intervention in extrahepatic portal vein obstruction in children.

## Preamble

Previous guidelines reviewing vascular disorders of the liver<sup>(1-3)</sup> focused on thrombosis of large vessels, such as the portal vein (PV) and hepatic vein (HV). However, increased understanding and research in hemostasis and bleeding in patients with cirrhosis has led to more diagnostic and therapeutic opportunities targeting prevention of bleeding, especially procedural bleeding. Therefore, this Guidance covers bleeding related to disturbances in the hemostatic system predisposed by chronic liver disease

as well as thrombosis, especially in the splanchnic vasculature.

This American Association for the Study of Liver Diseases (AASLD) Guidance provides a data-supported approach to the management of vascular liver disorders, portal (PVT) and hepatic vein thrombosis (HVT), and procedural bleeding in patients with liver disease. It differs from AASLD Guidelines, which are supported by systematic reviews of the literature, formal rating of the quality of evidence and strength of the recommendations, and, if appropriate, meta-analysis of results using the Grading of Recommendations Assessment Development and Evaluation system. In contrast, this document was developed by consensus of an expert panel and provides guidance statements based on formal review and analysis of the literature on the topics with oversight provided by the AASLD Practice Guidelines Committee at all stages of Guidance development. The AASLD Practice Guidelines Committee chose to commission a guidance on this topic because a sufficient number of randomized controlled trials were not available to support the development of a meaningful guideline.

View this article online at [wileyonlinelibrary.com](http://www.wileyonlinelibrary.com).  
DOI 10.1002/hep.31646

*Potential conflict of interest: Dr. Valla consults for Galmed and Intercept. Dr. Garcia-Pagan consults for Cook Medical, Gore, Shionogi, and Vifor. He received grants from Conatus, Theravance, Exalenz, and Mallinckrodt. Dr. Intagliata received grants from Dova. Dr. Roberts received grants from Sanofi.*

## ARTICLE INFORMATION:

From the <sup>1</sup>Division of Gastroenterology and Hepatology, Center for the Study of Hemostasis in Liver Disease, University of Virginia, Charlottesville, VA; <sup>2</sup>Barcelona Hepatic Hemodynamic Laboratory, Liver Unit, Hospital Clinic, Institut d'Investigacions Biomèdiques August Pi i Sunyer (IDIBAPS), University of Barcelona, Barcelona, Spain; <sup>3</sup>Centro de Investigación Biomédica en Red de Enfermedades Hepáticas y Digestivas (CIBERehd), Barcelona, Spain; <sup>4</sup>Health Care Provider of the European Reference Network on Rare Liver Disorders (ERN RARE-Liver), Barcelona, Spain; <sup>5</sup>Department of Internal Medicine, Section of Digestive Diseases, Yale University, New Haven, CT; <sup>6</sup>Veterans Administration Healthcare System, West Haven, CT; <sup>7</sup>Department of Transplant Surgery, Ann and Robert H. Lurie Children's Hospital of Chicago, Chicago, IL; <sup>8</sup>Department of Haematological Medicine, King's Thrombosis Centre, King's College Hospital National Health Service (NHS) Foundation Trust, London, United Kingdom; <sup>9</sup>Section of Hepatobiliary Surgery and Liver Transplantation, Surgical Research Laboratory, Department of Surgery, University Medical Centre Groningen, University of Groningen, Groningen, the Netherlands; <sup>10</sup>Hepatology Service, Hospital Beaujon, Clichy, France; <sup>11</sup>Health Care Provider of the European Reference Network on Rare Liver Disorders (ERN RARE-Liver), Barcelona, Spain.

## ADDRESS CORRESPONDENCE AND REPRINT REQUESTS TO:

Patrick G. Northup, M.D., M.H.S., F.A.A.S.L.D.  
Division of Gastroenterology and Hepatology  
Center for the Study of Hemostasis in Liver Disease  
University of Virginia

1215 Lee Street  
Charlottesville, VA 22908-0708  
E-mail: [pqn5qs@virginia.edu](mailto:pqn5qs@virginia.edu)  
Tel.: +1-434-243-6246

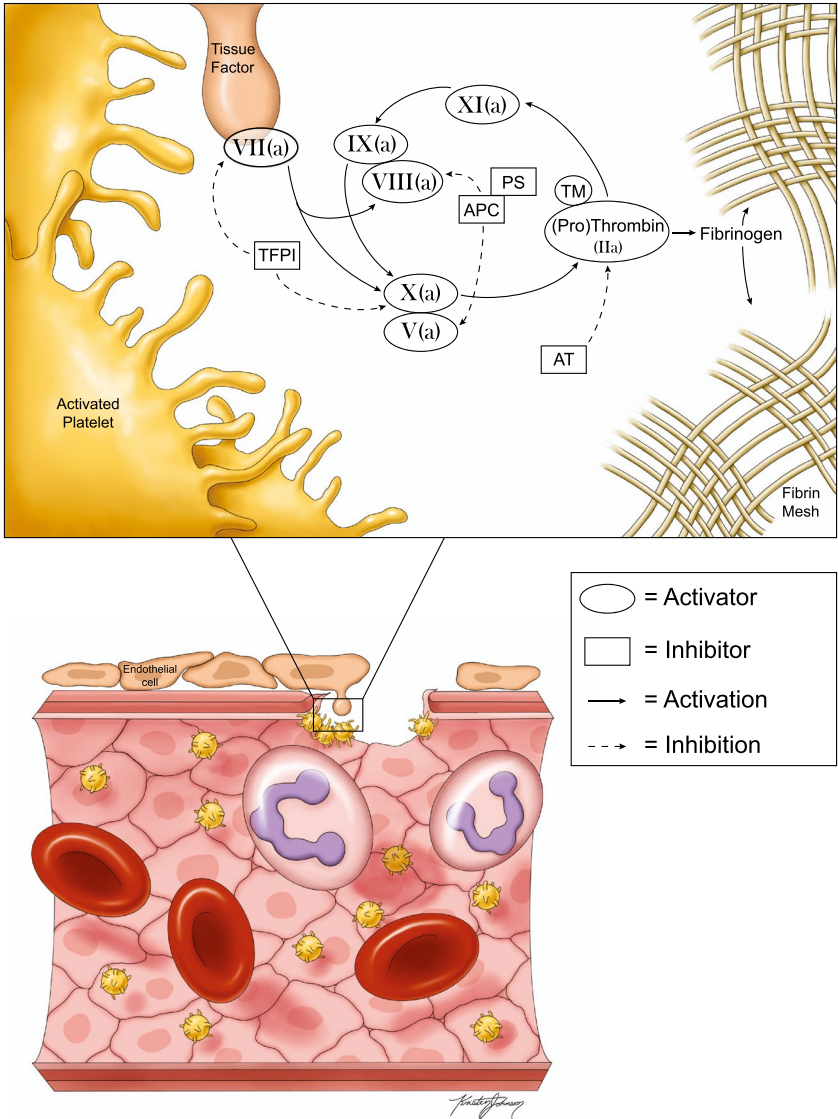
## Current Understanding of Coagulation and Hemostasis in Cirrhosis

Patients with cirrhosis have multiple alterations in their hemostatic system.<sup>(4)</sup> First, defective hepatic synthetic capacity results in decreased plasma levels of coagulation factors, inhibitors of coagulation, and fibrinolytic factors. Second, circulating platelet numbers are decreased because of a combination of decreased thrombopoietin (TPO) synthesis, splenomegaly with sequestration, accelerated platelet turnover, and decreased megakaryocyte production.<sup>(5)</sup> Third, plasma levels of hemostatic proteins that are primarily synthesized by endothelial cells are substantially elevated.<sup>(6)</sup> Fourth, low-grade intrahepatic and/or systemic activation of the hemostatic system results in consumption of hemostatic proteins.<sup>(7)</sup> Fifth, acquired disorders in platelet function and posttranslational modification of hemostatic proteins (e.g., fibrinogen) result in altered function.<sup>(8)</sup> There are many more hemostatic changes in patients with cirrhosis that are as yet unknown or not adequately characterized. Such changes include newly discovered roles of neutrophils<sup>(9)</sup> and red blood cells<sup>(10)</sup> in hemostasis and thrombosis; endothelial changes, including alterations in the endothelial glycocalyx<sup>(11,12)</sup>; and alterations in circulating levels of procoagulant microparticles.<sup>(13)</sup> Figure 1 provides an overview of the current understanding of the cellular-based hemostasis system in cirrhosis.

Hemostatic changes promoting bleeding and clotting occur simultaneously in any individual patient, and some of these changes counteract each other. For example, thrombocytopenia in cirrhosis is alleviated by elevated levels of the platelet adhesive protein, von Willebrand factor (VWF),<sup>(6)</sup> decreased levels of procoagulant proteins are counteracted by decreased levels of natural anticoagulant proteins,<sup>(14)</sup> and decreased levels of antifibrinolytic proteins are counteracted by decreased levels of profibrinolytics,<sup>(15)</sup> except in critically ill patients.<sup>(16)</sup> In view of these changes and clinical observations, cirrhosis is no longer considered a condition associated with an overall bleeding tendency, but rather both prohemostatic and antihemostatic

pathways are disturbed in complex ways, such that it is difficult to determine in an individual patient exactly where the balance is using currently available clinical tests.

Traditional laboratory measures of coagulation, such as prothrombin time (PT), international normalized ratio (INR), and activated partial thromboplastin time (aPTT), have proven inadequate and often misleading in the evaluation of hemostasis in cirrhosis because these measures only partially evaluate the hemostasis system and neglect the counterbalanced factors mentioned above (Table 1). Global tests of hemostasis, including plasma-based thrombin generation tests, plasma-based fibrinolysis assays, and whole-blood viscoelastic tests of clot formation, have been instrumental in developing the current concept of rebalanced hemostasis. For example, although traditional laboratory measures of coagulation may suggest a bleeding tendency, more advanced hemostasis tests, including plasma-based thrombin generation tests and whole-blood viscoelastic tests such as thromboelastography (TEG) or rotational thromboelastometry (ROTEM), have shown that patients with cirrhosis have normal to elevated thrombin-generating capacity and near-normal whole-blood clot formation.<sup>(4)</sup> Details of strengths and weaknesses of TEG and ROTEM in liver disease have been published.<sup>(17)</sup> Nevertheless, all currently available global hemostasis tests have limitations and should be interpreted cautiously because the predictive value of all available tests for spontaneous or procedural bleeding is unproven (Table 2). Whether global hemostasis tests are able to identify patients at risk for procedural bleeding has been poorly studied. Published data on viscoelastic tests, in particular, are contradictory because of a heterogeneous collection of subjects and procedures tested, a predominance of study procedures with a low risk of bleeding, poorly defined bleeding endpoints, and the use of fresh frozen plasma (FFP) transfusion in the standard-of-care arms.<sup>(18-22)</sup> However, because these tests are frequently within normal ranges in patients with cirrhosis, they may be useful in selecting which patients do not need preprocedural intervention. Because of the systematic underestimation of coagulation capacity by currently available viscoelastic testing methods,<sup>(23)</sup> abnormal preprocedural viscoelastic testing may still not require correction. Further study of viscoelastic testing with standardized clinical bleeding endpoints is needed.<sup>(24)</sup>



**FIG. 1.** The modern cell-based concept of the hemostasis and coagulation system in cirrhosis at the site of a vascular injury or rupture. Abbreviations: APC, activated protein C; AT, antithrombin; PS, protein S; TFPI, tissue factor pathway inhibitor; TM, thrombomodulin.

Although there are simultaneous changes in prohemostatic and antihemostatic pathways that have been interpreted to result in a reset in the hemostatic balance,<sup>(25)</sup> there are poorly understood distinct hypercoagulable and hypocoagulable features that may contribute to thrombosis or bleeding in any individual patient (Table 1).

## GUIDANCE STATEMENTS

- Simultaneous changes in procoagulant and anticoagulant pathways in patients with cirrhosis result in

complex hemostatic changes that are not adequately captured by traditional laboratory measures of hemostasis, such as PT, aPTT, and platelet count.

- Distinct hypercoagulable and hypocoagulable features may be present simultaneously in an individual patient and may contribute to thrombosis or bleeding, respectively.
- Global tests of hemostasis, such as thrombin generation or whole-blood viscoelastic tests, better capture the general hemostatic status of a patient with cirrhosis, but have not been clinically validated.



TABLE 1. Rebalance of Hemostasis System Components in Cirrhosis

	Platelets	Coagulation	Fibrinogen	Fibrinolysis
Changes promoting bleeding	<ul style="list-style-type: none"><li>• Thrombocytopenia</li><li>• Platelet function defects</li><li>• Anemia (less platelet margination when hematocrit is low)</li></ul>	<ul style="list-style-type: none"><li>• Low levels of factors II, V, VII, IX, X, and XI</li><li>• Decreased platelet procoagulant surface</li></ul>	<ul style="list-style-type: none"><li>• Low plasma levels</li><li>• Hypersialylation leading to decreased rates of fibrin polymerization</li><li>• Low FXIII</li></ul>	<ul style="list-style-type: none"><li>• Elevated tPA not balanced by elevated plasminogen activator inhibitor-1</li><li>• Low levels of <math>\alpha</math>2-antiplasmin and TAFI</li></ul>
Changes promoting clotting	<ul style="list-style-type: none"><li>• Elevated levels of VWF</li><li>• Decreased levels of ADAMTS13</li><li>• Enhanced <i>in vivo</i> platelet activation</li><li>• Activated endothelium</li></ul>	<ul style="list-style-type: none"><li>• Low levels of protein C and S and antithrombin; elevated factor VIII</li></ul>	<ul style="list-style-type: none"><li>• Decreased permeability of the fibrin clot</li></ul>	<ul style="list-style-type: none"><li>• Low plasminogen</li></ul>
Net effect	Poorly studied; elevated VWF compensates at least partly for thrombocytopenia	Normal to enhanced thrombin-generating capacity	Poorly studied	Controversial; decompensation appears to favor hyperfibrinolysis, but ACLF/sepsis can severely inhibit fibrinolysis

Abbreviations: ADAMTS13, a disintegrin and metalloproteinase thrombospondin type 1 motif 13; TAFI, thrombin activatable fibrinolysis inhibitor.

# Procedural Bleeding in Patients With Cirrhosis

Procedure-related bleeding in patients with cirrhosis may be a consequence of hemostatic failure, but many bleeding events arise as a consequence of unrelated factors, such as portal hypertension or vessel rupture/puncture. These types of bleeding events are therefore not preventable with preprocedural manipulation of the hemostasis system, although major nonhemostatic bleeding events may eventually turn into hemostatic bleeds because of the consumption of hemostatic proteins. Consequently, clinicians routinely face complex dilemmas when assessing procedural bleeding risk because bleeding can occur from different underlying causes (Fig. 2). Interventions directed at preventing and treating bleeding should specifically target the expected or actual source of bleeding (e.g., vessel rupture, portal hypertension, or hemostatic failure).

## Bleeding Risk Stratification

Assessment of bleeding risk for any particular procedure is dependent on numerous factors that can be broadly grouped into procedural- or technical-related factors, disease-state characteristics inherent to cirrhosis, and systemic factors.<sup>(26-32)</sup> Although these factors are interdependent and vary over time, understanding each component's relative contribution to bleeding risk is important when estimating risk. Past studies have grouped both low- and high-risk procedure types together to derive broader conclusions with respect to an overall bleeding risk,<sup>(18,33-35)</sup> but procedure risk stratification should be based on specific procedure type when data are available.

## Procedural and Technical Factors

In previous guidance statements and expert opinion documents, procedure bleeding risk has been categorized as low or high (Table 3).<sup>(26,28,29)</sup> Low-risk procedures constitute all procedures whereby major bleeding is expected to occur in <1.5% of cases

TABLE 2. Advantages and Limitations of Diagnostic Laboratory and Research Tests Measuring Hemostasis and Procedural Bleeding Risk in Patients With Cirrhosis

Test*	Diagnostic or Research	Advantages	Limitations	Predictive Value for Procedural or Spontaneous Bleeding in Patients With Cirrhosis
Platelet count	Diagnostic	Easily accessible; marker of portal hypertension and sequestration	No relation to platelet function; does not take into account the role of elevated VWF in compensating for the thrombocytopenia of cirrhosis	Some, but not all, studies suggest an increased bleeding risk with lower platelet count, but this may simply reflect increased severity of disease or portal hypertension. Whether normalization of platelet count reduces bleeding risk is unknown.
Platelet aggregation	Diagnostic	Test of platelet function in response to multiple agonists	Unreliable in thrombocytopenic samples and therefore underestimates platelet function in thrombocytopenia	Unknown
Flow-based platelet function tests	Diagnostic (PFA-100/200) and research	Test of platelet function; sensitive for VWF	Sensitive to anemia and thrombocytopenia and therefore does not give information on intrinsic platelet function	Unknown
Flow cytometry based-platelet function tests	Research	Not dependent on platelet count and therefore gives information on intrinsic platelet function in response to various agonists	Only tests activation, not aggregation	Unknown
PT/aPTT	Diagnostic	Easily accessible; PT is a marker of liver disease severity	Only sensitive for procoagulant proteins and is therefore unsuitable to assess hemostatic competency; laboratory-to-laboratory variation, which may result in clinically relevant differences in MELD scores	No predictive value
Fibrinogen	Diagnostic	Easily accessible	Unclear what fibrinogen levels are required for hemostasis in patients with liver disease; does not take into account potential structural changes in the fibrin clot	Some studies suggest that low fibrinogen increases bleeding risk, but this may simply reflect increasing severity of liver disease. Normalization of fibrinogen levels does not appear to reduce bleeding risk.
Thrombin generation	Research	Gives an adequate representation of coagulation balance, particularly when modified with thrombomodulin or other protein C activators	Cumbersome test, although an automated analyzer (Genesis-ST) has been developed. Whole-blood variants are in development, which may be useful as point-of-care tests.	Unknown
TEG/ROTEM	Diagnostic	Point-of-care test that gives a much better estimate of hemostatic balance than other readily available diagnostic tests; helpful in transfusion management in bleeding patients	Insensitive for VWF and protein C and therefore likely underestimates hemostatic competency. Older devices require experienced operators and suffer from laboratory-to-laboratory variation. New-generation devices are less operator dependent.	Unclear; some studies have shown predictive value, whereas others have not. Unknown whether normalization of TEG or ROTEM parameters reduces bleeding risk
Markers of activation of platelets, coagulation, and fibrinolysis (platelet factor 4, soluble CD40 ligand, D-dimer, prothrombin fragment F1 + 2, thrombin antithrombin complex, plasmin- $\alpha$ 2-antiplasmin, and others)	Diagnostic (D-dimer) and research	These markers give a representation of hemostatic processes that are ongoing in the test subject, whereas tests such as PT/aPTT/thrombin generation/TEG/ROTEM assess hemostatic potential.	These markers are cleared by the liver, and it is uncertain whether elevated levels represent actual ongoing platelet activation, coagulation, or fibrinolysis or accumulation of these markers by reduced clearance.	Unknown

TABLE 2. Continued

Test*	Diagnostic or Research	Advantages	Limitations	Predictive Value for Procedural or Spontaneous Bleeding in Patients With Cirrhosis
Fibrinolysis in TEG/ROTEM	Diagnostic	Rapid, point-of-care test	Only sensitive for profound hyperfibrinolysis	May have predictive value during liver transplantation and other major operative procedures or severe hemorrhage
Plasma-based fibrinolysis tests	Research	Sensitive for all profibrinolytic and antifibrinolytic factors; hypofibrinolysis associated with venous and arterial thrombotic risk in general population; hypofibrinolytic state associated with poor outcome in critically ill patients with cirrhosis	Relation between hyperfibrinolysis and bleeding has not been established	Unknown
Ratios (FVIII/protein C or thrombin generation with and without protein C activator)	Research	May predict thrombotic events; may be markers of a hypercoagulable state	May be confusing and misinterpreted. Biological plausibility of a FVIII protein C ratio is unclear; a thrombin generation ratio is a measure of functionality of the protein C system, not of global hypercoagulability.	May have predictive value for PVT, not bleeding

\*Some tests are only available in the research setting. Abbreviation: PFA, platelet function analyzer.

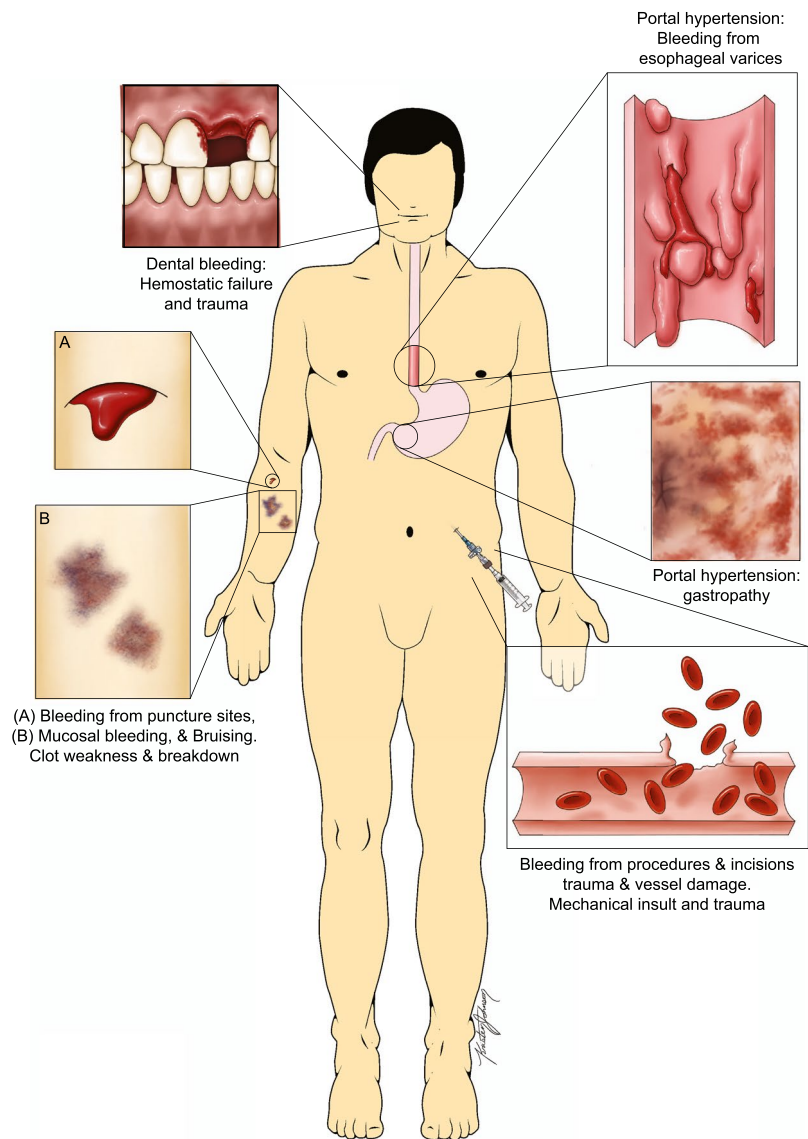
and/or significant bleeding, if it occurs, can be easily controlled. Conversely, high-risk procedures have increased risk of bleeding (estimated >1.5% risk of major bleeding) and/or hemorrhage, if it occurs, can be difficult to control or may lead to catastrophic consequences, even in small amounts (e.g., central nervous system bleeding).<sup>(26,28)</sup> This risk dichotomy is based on expert opinion and generally grounded in the context of periprocedural therapeutic anticoagulation, but provides a useful framework when engaging in multidisciplinary planning before procedures.

An individual procedure will involve different technical risks. Both provider experience and technique directly affect outcomes. For example, the use of imaging with ultrasound guidance for thoracentesis in patients with abnormal coagulation parameters reduces the risk of bleeding.<sup>(36)</sup> Similarly, the use of ultrasound guidance for PV access during transjugular intrahepatic portosystemic shunt (TIPS) reduces the risk of capsule perforation, a known precipitant of intraperitoneal hemorrhage.<sup>(37)</sup> Although factors such as technique and operator experience are often discussed, they are difficult to quantify and study systematically, but should be considered in procedure risk stratification. Another important factor inherent to each individual procedural technique is the ability to control active bleeding if it occurs. For example, significant bleeding after dental extractions is often prevented with local hemostatic measures, even in patients with advanced cirrhosis, significant thrombocytopenia, and elevated INR.<sup>(38,39)</sup>

Liver Disease Factors

Patients with cirrhosis can present with a wide spectrum of diseases, from well-compensated cirrhosis to chronic decompensation to acute decompensation with multiorgan failure.<sup>(40)</sup> Advanced liver disease is associated with thrombocytopenia attributable to portal hypertension and a prolonged INR as a result of an impaired synthesis of coagulation factors. Although these coagulation indices are historically used to assess bleeding risk, they are misleading in patients with cirrhosis.

Advanced portal hypertension is an independent risk factor for procedure-related bleeding, even in low-risk procedures,<sup>(41,42)</sup> but there are factors that may confound this finding. The hemostatic system is



**FIG. 2.** Depiction of various types of bleeding that a patient with cirrhosis might experience. Some bleeding sources are related to vascular trauma, some to excessive portal hypertension, and some to hemostatic failure. Other common sources not shown include portal hypertensive enteropathy/colopathy, rectal varices (portal hypertensive), epistaxis (mechanical or hemostatic), and menorrhagia (hemostatic).

affected by hepatic decompensation, and patients with cirrhosis are at risk of becoming critically ill, requiring exposure to multiple procedures and potentially increasing the risk of bleeding complications.<sup>(43,44)</sup> Acute decompensation of cirrhosis and acute-on-chronic liver failure (ACLF) directly alter the hemostatic system.<sup>(16,45,46)</sup> A retrospective case-control study demonstrated that patients with ACLF had a higher risk of hemorrhage after paracentesis, and low fibrinogen levels were associated with this risk.<sup>(47)</sup> Of

note, there were no significant differences between platelet and INR levels between matched controls and patients with bleeding, and neither factor was predictive of bleeding on multivariable analysis. The systemic inflammatory response and association with concurrent infection alter hemostatic function, as measured by global hemostasis testing, and may be associated with an increased risk of bleeding, particularly in the setting of invasive procedures. Overall, data remain sparse on the independent influence of



TABLE 3. Bleeding Risk Stratification of Common Procedures in Patients With Cirrhosis

	Low Risk	High Risk
Percutaneous	<ul style="list-style-type: none"><li>• Paracentesis</li><li>• Thoracentesis</li><li>• Drainage catheter exchange</li></ul>	<ul style="list-style-type: none"><li>• Biliary intervention (cholecystostomy or percutaneous biliary drain)</li><li>• Liver biopsy</li><li>• Tumor ablation</li><li>• Nonliver intraabdominal solid-organ biopsy</li><li>• Intrathoracic organ biopsy</li><li>• Nephrostomy tube placement</li><li>• Central nervous system procedures</li><li>• Intraocular procedures/injections</li><li>• Intra-articular injections</li></ul>
Vascular	<ul style="list-style-type: none"><li>• Peripherally inserted central catheter line placement</li><li>• Central venous catheter placement</li><li>• Central line removal</li><li>• IVC filter placement</li><li>• Diagnostic venography</li><li>• Coronary angiography and right heart catheterization (diagnostic)</li></ul>	<ul style="list-style-type: none"><li>• TIPS</li><li>• Angiography or venography with intervention</li><li>• Transjugular liver biopsy</li><li>• Transhepatic arterial chemoembolization or radioembolization</li><li>• Therapeutic coronary angiography</li></ul>
Endoscopic	<ul style="list-style-type: none"><li>• Diagnostic esophagogastroduodenoscopy and routine variceal band ligation</li><li>• Enteroscopy</li><li>• Colonoscopy (including mucosal biopsy)</li><li>• Endoscopic retrograde cholangiopancreatography without sphincterotomy</li><li>• Capsule endoscopy</li><li>• Endoscopic ultrasound without fine-needle aspiration</li><li>• Transesophageal echocardiogram</li><li>• Diagnostic bronchoscopy without biopsy</li></ul>	<ul style="list-style-type: none"><li>• Endoscopic polypectomy</li><li>• Endoscopic stricture dilation or mucosal resection</li><li>• Balloon-assisted enteroscopy</li><li>• Percutaneous endoscopic gastrostomy placement</li><li>• Endoscopic retrograde cholangiopancreatography with sphincterotomy</li><li>• Endoscopic ultrasound with fine-needle aspiration</li><li>• Cystgastrostomy</li><li>• Therapeutic bronchoscopy or diagnostic bronchoscopy with biopsy</li></ul>
Other	<ul style="list-style-type: none"><li>• Skin biopsy</li><li>• Dental cleaning and nonextraction procedures</li></ul>	<ul style="list-style-type: none"><li>• Dental extraction</li></ul>

A procedure is considered high risk if major bleeding is expected in >1.5% of procedures or if even minor bleeding is likely to result in permanent organ damage or death.<sup>(28–30,32)</sup>

advanced portal hypertension, acute decompensation, and ACLF in hemostasis; however, it is likely that patients with these disorders are at higher risk of procedural bleeding, and careful consideration in preprocedural planning is recommended.

Systemic Factors

Patients with cirrhosis often have multiple medical comorbidities that may affect overall bleeding risk. Among these, acute and chronic kidney disease (CKD) have been most extensively studied as risk factors for bleeding. Underlying alteration in coagulation factors may play a role in the association of bleeding risk and acute kidney injury (AKI).<sup>(48,49)</sup> One study examined patients with postparacentesis hemorrhage and found an association between AKI and bleeding, independent of infection.<sup>(50)</sup> In a large retrospective analysis of large-volume paracentesis,

nine bleeding events out of 4,729 procedures were reported, and renal dysfunction was reported in 89% of patients (8 of 9 patients) with bleeding events.<sup>(51)</sup> A study examining postbanding ulcer bleeding after endoscopic variceal ligation (EVL) demonstrated that patients who developed bleeding (n = 6) compared to those who did not (n = 259) had significantly higher serum creatinine (2.2 mg/dL bleeders vs. 1.0 mg/dL nonbleeders; *P* = 0.001).<sup>(52)</sup> In this study, there was no significant difference in platelet level and INR between patients with bleeding and those without bleeding. Based on these data, addressing acute and/or chronic kidney dysfunction as much as possible before elective procedures is recommended.

Medications, in particular antiplatelet therapy and anticoagulation, alter the risk of bleeding during procedures and should be carefully considered in the periprocedural period. In a retrospective cohort analysis comparing hospitalized patients with cirrhosis receiving venous thromboembolism (VTE)

prophylaxis to those who did not, there was a trend of increased nongastrointestinal bleeding events in patients receiving VTE prophylaxis (64% of nongastrointestinal bleeding events were procedure-related bleeding).<sup>(53)</sup> On multivariable analysis, the use of VTE prophylaxis in this cohort (OR, 2.36; CI, 1.12–4.97;  $P = 0.025$ ) was associated with overall in-hospital bleeding, yet platelet count, INR, and Model for End-Stage Liver Disease (MELD) score were not predictive of bleeding. However, in a study examining post-EVL ulcer bleeding, the use of therapeutic low-molecular-weight heparin (LMWH) was not associated with bleeding.<sup>(52)</sup> More data are needed to better understand the effect of anticoagulation on bleeding risk with specific procedures in patients with cirrhosis.

## Examples of Common Procedure Risk Assessment in Patients With Cirrhosis

Procedures are routinely performed in patients with cirrhosis (e.g., paracentesis and endoscopy) with very low risk of bleeding in the presence of elevated INR and thrombocytopenia.<sup>(41,54,55)</sup> Therefore, the use of prophylactic transfusions of FFP and/or platelets based on preprocedural laboratory tests is not routinely indicated.<sup>(56)</sup> For example, a study of 1,100 therapeutic paracenteses in 628 patients (513 with cirrhosis) and no prophylactic transfusion before the procedure showed no bleeding or complications requiring hospitalization in any patient (292 patients with INR > 2; 598 patients with platelets < 50,000/ $\mu$ L).<sup>(55)</sup> EVL can lead to delayed postbanding ulcer bleeding in patients with cirrhosis. In one study of 150 patients with cirrhosis undergoing EVL, traditional hemostasis testing (elevated INR and thrombocytopenia) was not predictive of EVL bleeding, but advanced cirrhosis (Child-Turcotte-Pugh [CTP] C) was the most important factor associated with risk of post-EVL ulcer bleeding.<sup>(42)</sup> This finding has been reproduced in other studies.<sup>(57)</sup> Because EVL bleeding is typically delayed by several days, prophylactic measures before or during the procedure will likely not alter post-EVL bleeding risk. As such, the use of prophylaxis, based on traditional measures of hemostasis before EVL, is not

recommended. The risk of bleeding with liver biopsy, either percutaneous or transjugular, is low in the general population, but may be higher in patients with cirrhosis.<sup>(58–61)</sup> Historically, traditional hemostasis studies do not correlate with bleeding risk in patients undergoing liver biopsy.<sup>(58,62)</sup> One study of 2,740 percutaneous liver biopsies performed in patients with advanced fibrosis or well-compensated cirrhosis documented a 0.6% bleeding rate with no bleeding-related deaths.<sup>(61)</sup> Data from this study suggest an association with thrombocytopenia (<60,000/ $\mu$ L) and elevated INR (>1.3) and postbiopsy hemorrhage.<sup>(61)</sup> Because of the conflicting data in the literature, current AASLD guideline recommendations on liver biopsy do not identify a specific INR or platelet cutoff in which the risk of bleeding is substantially increased, but suggest individualized approaches and assessment of other risk factors that may increase bleeding risk,<sup>(60)</sup> as discussed above.

## GUIDANCE STATEMENTS

- Determining procedural bleeding risk is complex and requires collaboration between specialists to determine the level of bleeding risk before procedures and aid in periprocedural hemostasis management.
- Because of conflicting data in the literature, there is no data-driven specific INR or platelet cutoff in which procedural bleeding risk is reliably increased.
- Identification and correction of modifiable risk factors for bleeding before performing procedures, particularly high-risk elective procedures, is recommended. Such risk factors include the use of anti-thrombotic drugs, AKI, and infection.

## Preprocedural Interventions to Prevent Bleeding

The preparation and intraoperative management of patients with cirrhosis undergoing major surgery, including liver transplantation (LT), has been described.<sup>(63)</sup> However, it is important to note that data suggest that LT surgery can be safely performed without prophylactic or protocol-driven preprocedural administration of blood, FFP, or platelets.<sup>(64)</sup>

In the general medical population, it has been well established that preprocedural hemostasis laboratory testing serves little purpose unless patients have a history of bleeding or an inherited bleeding disorder or are using antithrombotic drugs.<sup>(65)</sup> Because patients with cirrhosis often do have a bleeding history and because of the known hemostatic abnormalities of these patients, preprocedural hemostasis testing is very common. In the following sections, we argue that there is little evidence that correction of hemostatic laboratory abnormalities before common procedures decreases bleeding risk.

## Platelet Interventions and Therapies Targeting Primary Hemostasis

*In vitro* data have been interpreted to suggest platelet levels  $>55,000/\mu\text{L}$ <sup>(66)</sup> improve hemostasis in patients with cirrhosis. However, these *in vitro* data have only assessed platelet procoagulant activity and have not accounted for potential compensation by VWF and other endothelial-based components. In addition, this threshold has not been validated clinically. Data suggest that platelet transfusions do not substantially improve thrombin generation capacity or viscoelastic markers of bleeding risk.<sup>(67)</sup> Furthermore, despite modest rises in absolute platelet counts, they carry a potential for the transfusion-related lung injury syndromes.<sup>(68)</sup>

The data on a threshold platelet level for bleeding risk minimization before procedures are mixed. Some studies have shown no predictive value of preprocedural peripheral platelet count on procedural bleeding complications.<sup>(69,70)</sup> In a prospective cohort study of critically ill patients, of whom 211 had cirrhosis, the most common bleeding events were spontaneous gastrointestinal or variceal bleeding; however, 10 events (occurring in 4.7% of the entire cohort of patients with cirrhosis) were postprocedural or postoperative.<sup>(71)</sup> In this cohort, although a peripheral platelet count of  $<30,000/\mu\text{L}$  was associated with bleeding, most of the bleeding was attributable to portal hypertension. Another study of 50 LT candidates with platelet counts  $<125,000/\mu\text{L}$  (52% with counts  $<75,000/\mu\text{L}$ ) were followed for procedural complications.<sup>(33)</sup> There

were 10 (20%) bleeding complications after procedures, all of which occurred in patients with a platelet count  $<75,000/\mu\text{L}$ . Despite this finding, patients in this study who received prophylactic platelet transfusion before the procedures were paradoxically more likely to experience bleeding. Therefore, this suggests that the low platelet count may have been merely a reflection of advanced portal hypertension and not a causative risk factor for bleeding.

There are three medications approved by the U.S. Food and Drug Administration (FDA) for increasing platelet counts in patients with cirrhosis. All of these agents are TPO receptor agonists and stimulate bone marrow production of platelets. Eltrombopag has the obsolete indication for treatment of thrombocytopenia related to interferon-based hepatitis C therapy and is now rarely used in the prophylactic role. However, an early study of this agent designed to produce platelet counts in the “healthy normal” range before invasive procedures in patients with cirrhosis was discontinued early because of excess thrombotic events, particularly PVT, in the treatment arm, possibly related to excessively high platelet counts.<sup>(72)</sup> Avatrombopag<sup>(35)</sup> and lusutrombopag<sup>(34)</sup> are indicated for the treatment of thrombocytopenia in adult patients with chronic liver disease who are scheduled to undergo a procedure. Each of these oral agents requires completion of a 2- to 8-day course preceding the scheduled procedure. These agents are superior to placebo in achieving a target platelet count  $\geq 50,000/\mu\text{L}$  before the procedure, with no statistical differences in thrombotic complications compared to placebo. Of note, there were no statistical differences in postprocedural bleeding events in these studies between treatment arm and placebo, and therefore routine use of these agents to prevent procedure-related bleeding cannot be recommended.

There are no high-quality data on appropriate platelet thresholds before procedures, and general interventions to increase platelet counts to prevent bleeding are not evidence based and cannot be recommended. Given the low bleeding risk of many common procedures, potential risks of platelet transfusion, lack of evidence that elevating the platelet count reduces bleeding risk, and ability to use interventions, including transfusion and hemostasis procedures on an as-needed basis if bleeding occurs, it is reasonable to perform both low- and high-risk procedures without prophylactically treating the platelet count. This recommendation deviates from recommendations by

other societies (Table 4), and, ideally, studies with clinical bleeding endpoints and placebo controls are required to examine the best strategy for periprocedural platelet management. Understanding the inconsistency of various societal recommendations and multidisciplinary nature of procedural health care, an individualized approach to patients with severe thrombocytopenia before procedures is recommended because of the lack of definitive evidence for safety and efficacy of interventions intended to increase platelet counts in patients with cirrhosis.

1-Deamino-8-D-arginine vasopressin (DDAVP) increases release of endothelial VWF. A randomized controlled trial using intranasal administration of DDAVP showed equivalent postprocedural bleeding rates compared with platelet and FFP transfusions preceding dental extractions in patients with cirrhosis with INR between 2 and 3 and/or platelet count between 30,000 and 50,000/ $\mu$ L.<sup>(73)</sup> The mechanism of action of DDAVP in this study was not clear, and DDAVP was shown to not affect primary hemostasis or platelet adhesion in another study of patients with cirrhosis.<sup>(74)</sup>

## GUIDANCE STATEMENTS

- Given the low risk of bleeding of many common procedures, potential risks of platelet transfusion, lack of evidence that elevating the platelet count reduces bleeding risk, and ability to use effective interventions, including transfusion and hemostasis if bleeding occurs, it is reasonable to perform both low- and high-risk procedures without prophylactically correcting the platelet count.
- An individualized approach to patients with severe thrombocytopenia before procedures is recommended because of the lack of definitive evidence

for safety and efficacy of interventions intended to increase platelet counts in patients with cirrhosis.

## Coagulation Interventions and Therapies Targeting Procoagulant Factor Deficiencies

As discussed above, the PT and its derivative, the INR, are widely available traditional measures of coagulation. However, because the INR only assesses quantitative defects in procoagulant clotting factors (Tables 1 and 2), it is not a reliable indicator of hemostatic balance in patients with cirrhosis and is unable to predict procedural bleeding risk. The literature on the INR's poor predictive value in procedural bleeding is extensive.<sup>(42,55,60,75-77)</sup> However, INR is a surrogate indicator of protein synthetic functional capacity of the liver and may correlate with bleeding risk related to severity of liver disease, rather than bleeding risk related directly to hemostatic failure.

FFP transfusions carry important risks: (1) a potential for developing transfusion-related lung injury syndromes<sup>(68)</sup> and (2) increases in portal pressures directly proportional to the volume transfused.<sup>(78)</sup> Importantly, FFP transfusions show minimal efficacy in improving thrombin generation capacity *in vitro*.<sup>(79)</sup> Outside of advanced malnutrition states or chronic cholestasis, vitamin K replacement has no measurable effect on the INR in patients with cirrhosis. Determination of factor V levels can aid the practitioner in differentiating vitamin K deficiency from impaired liver function

**TABLE 4. Recommendations of Selected Professional Societies for Minimum Threshold Values of Common Coagulation and Bleeding Parameters in Patients With Cirrhosis Before Invasive Procedures With a High Risk of Bleeding**

Organization	Platelet Count ( $\times 1,000/\mu$ L)	INR	Fibrinogen Level (mg/dL)
AASLD (this document)	No routine preprocedure correction	No routine preprocedure correction	No routine preprocedure correction
Society of Interventional Radiology 2019 <sup>(28)</sup>	>30	<2.5*	>100
American Gastroenterological Association 2019 <sup>(81)</sup>	>50	No correction	>120
American College of Gastroenterology 2020 <sup>(3)</sup>	>50	No correction	>120-150

Generally, there are no minimum threshold levels for any of the laboratory values recommended for procedures with a low risk of bleeding. Each specific guidance document specifies threshold values to achieve before the procedure to reduce bleeding risk. Specific recommendations on the preprocedural intervention recommended to reach threshold values vary by society.

\*Correction of INR using vitamin K, not FFP, is recommended by this society.



if the diagnosis is in question. Given the lack of effect of FFP on hemostatic capacity in the population of patients with cirrhosis, we advise against prophylactic FFP transfusion before common procedures and await studies with clinically relevant endpoints to yield further guidance. This recommendation is consistent with the AASLD practice guidelines for management of ascites<sup>(56)</sup> and portal hypertensive bleeding<sup>(80)</sup> as well as other professional society guidelines.<sup>(3,28,81,82)</sup>

Recombinant factor VIIa is effective in normalizing the INR in patients with cirrhosis, yet a randomized clinical trial showed no benefit in controlling esophageal variceal hemorrhage.<sup>(83)</sup> Its use in a prophylactic setting before invasive procedures is not recommended, and the use of this agent in nonhemophilia patients has been associated with increased risks of thrombosis, including arterial thromboses.<sup>(84)</sup> Prothrombin complex concentrates targeting both the deficiency of the procoagulant system as well as the acquired deficiency of the innate anticoagulant system are under study in patients with liver disease,<sup>(85,86)</sup> but efficacy and safety data are lacking to date.

## GUIDANCE STATEMENTS

- The INR should not be used to gauge procedural bleeding risk in patients with cirrhosis who are not taking vitamin K antagonists (VKAs).
- Measures aimed at reducing the INR are not recommended before procedures in patients with cirrhosis who are not taking VKAs.
- FFP transfusion before procedures is associated with risks and no proven benefits.

## Fibrinogen and Therapies Targeting Excessive or Inappropriate Fibrinolysis

Plasma fibrinogen levels <100 mg/dL are associated with spontaneous and procedure-related bleeding in patients with cirrhosis,<sup>(71,87)</sup> but causal relationships are not established. Low fibrinogen levels may reflect critical illness and do not directly cause bleeding in most cases. In a case series of critically ill surgical patients without cirrhosis, a fibrinogen level of  $\geq 100$  mg/dL resulted in greater

mechanical clot stability compared to lower levels of fibrinogen, but the relationship was relatively linear without an obvious threshold effect.<sup>(88)</sup> The literature on fibrinogen replacement for bleeding is derived from trauma literature or advanced fibrinolytic states during cardiac surgery and LT. Diagnostic laboratory tests for hyperfibrinolysis are not readily available in clinical practice, and current viscoelastic testing is not sensitive for moderate or mild hyperfibrinolysis. The diagnosis of hyperfibrinolytic postprocedural bleeding is made clinically because laboratory testing is not reliable for this condition. Typical manifestations include continuous venous oozing from skin puncture sites and persistent mucosal or submucosal bleeding. Epsilon-aminocaproic acid (EACA), a lysine analogue that prevents plasminogen and tissue plasminogen activator (tPA) from binding to fibrin, has shown benefit in stopping fibrinolytic bleeding without major toxicity in an uncontrolled case series.<sup>(89)</sup> In patients without cirrhosis, some benefits of antifibrinolytic therapy are observed after dental extractions in patients on continuous therapeutic anticoagulants.<sup>(90)</sup> There are no definitive data supporting the use of EACA for prevention of bleeding in cirrhosis, although elective procedures should be delayed during states of clinically apparent pathological fibrinolysis. Tranexamic acid has antifibrinolytic activity through a similar mechanism as EACA. A recent international multicenter, randomized, double-blind, placebo-controlled trial of high-dose tranexamic acid as an adjunctive therapy in patients presenting with acute gastrointestinal bleeding showed no reduction in death or bleeding in the tranexamic acid arm.<sup>(91)</sup> This study population included a minority of patients with cirrhosis, and a subgroup analysis showed the risk of VTE events to be higher in patients with cirrhosis receiving the tranexamic acid. Until further supportive data are published, the prophylactic use of EACA or tranexamic acid to prevent procedural bleeding cannot be recommended.

Because fibrin and its precursor, fibrinogen, are key components of functional clot formation, until definitive clinical trial data are available, it is logical to maintain blood levels of this factor to promote the ability to form strong and functional clots. Therefore, correction of plasma fibrinogen to levels  $>100$  mg/dL using cryoprecipitate or fibrinogen

concentrate before high-risk procedures could be considered for patients with cirrhosis, but data to support this strategy reducing bleeding complications are lacking. Regardless, levels of fibrinogen of <100 mg/dL are rare in patients with cirrhosis outside of acute critical illness.

### GUIDANCE STATEMENTS

- Low fibrinogen levels have been associated with increased bleeding risk in critically ill patients with cirrhosis.
- Cryoprecipitate and fibrinogen factor replacements are low-volume products effective at increasing fibrinogen levels.

## Portal Vein Thrombosis

### TERMINOLOGY AND CLASSIFICATION SYSTEMS

PVT is a heterogeneous condition with respect to etiology, manifestations, natural history, and therapeutic options. For this reason, terminology and classification systems also vary extensively in the literature. It is desirable to establish standardized terminology in describing PVT to allow comparison and external validation of future studies. In regard to the time course of thrombosis, the term “recent” is preferred to the term “acute” because the latter implies both clinical symptoms as well as recent-onset thrombosis, yet not all patients with a recent PVT develop symptoms. Precise dating can be impossible in patients without recent suggestive symptoms or previous abdominal imaging and is often done retrospectively. The term “chronic” should be applied to a PV obstruction persisting longer than 6 months after presumed onset. Although somewhat arbitrary, 6 months has some justification based on a pivotal prospective, longitudinal study in 100 patients with recent PVT followed up until 1 year. In this study, recanalization that did not take place within 6 months did not occur between 6 and 12 months, and cavernous transformation developed in most such patients despite anticoagulation therapy.<sup>(92)</sup> Following the onset of a PV obstruction that is not followed by regression, cavernous transformation may develop within a few weeks regardless of the cause of obstruction. Therefore, when portal

TABLE 5. Recommended Standardized Nomenclature for Description of PVT in Both the Clinical and Research Setting

Descriptor	Definition
Time course	
Recent	PVT presumed to be present for <6 months
Chronic	PVT present or persistent for >6 months
Percent occlusion of main PV	
Completely occlusive	No persistent lumen
Partially occlusive	Clot obstructing >50% of original vessel lumen
Minimally occlusive	Clot obstructing <50% of original vessel lumen
Cavernous transformation	Gross portoportal collaterals without original PV seen
Response to treatment or interval change	
Progressive	Thrombus increases in size or progresses to more complete occlusion
Stable	No appreciable change in size or occlusion
Regressive	Thrombus decreases in size or degree of occlusion

cavernous transformation is present, this term should be preferred to “chronic portal vein thrombosis” for descriptive and systematic categorization. Table 5 outlines a simplified nomenclature system that can be used in future publications and research to allow comparison between studies and classification systems. In addition to time course, extent and response to treatment are major areas in which consistency in nomenclature is desirable, but quantitative assessments for these endpoints are largely lacking in current clinical practice.

Various classification systems have been proposed to group PVT variants into broad categories. An overview of the major published PVT classification systems is presented in Table 6. The majority of these systems were developed exclusively in the LT population, and clinical outcome correlations are mostly limited to short-term LT recovery and survival.<sup>(93-98)</sup> Some researchers have correlated PVT location and extent with clinical outcomes in patients with cirrhosis outside of pure transplant outcomes,<sup>(99,100)</sup> but long-term outcome data are also lacking in nontransplant recipients. A recently proposed system combines multiple components, including location, degree of occlusion, time course, and presence of underlying liver disease, but is complex and lacks any clinical outcome correlation.<sup>(101)</sup> Further longitudinal, prospective studies using standardized categorization systems

TABLE 6. Summary of Major Published PVT Classification Systems and Their Strengths and Weaknesses

System	Classification Type	Categories	Outcome Correlation	Strengths	Weaknesses
Sieber et al., 1991 <sup>(93)</sup>	Anatomical	<ul style="list-style-type: none"> <li>Partial</li> <li>Complete PV occlusion</li> <li>Extensive with mesenteric involvement</li> </ul>	Posttransplant survival	First systematic report; correlates with perioperative death in early LT series	Only anatomical classes and exclusive to LT patients
Nonami et al., 1992 <sup>(94)</sup>	Anatomical	<ul style="list-style-type: none"> <li>Intrahepatic</li> <li>Primary PV branch</li> <li>Main PV trunk</li> <li>Mesenteric plus main trunk</li> </ul>	Correlated with severity of portal hypertension pretransplant	Large series of early LT patients with anatomical PVT location described	Only patients evaluated at the time of LT
Gayowski et al., 1996 <sup>(95)</sup>	Anatomical	<ul style="list-style-type: none"> <li>Intrahepatic</li> <li>Primary PV branch</li> <li>Main PV trunk</li> <li>Mesenteric plus main trunk</li> </ul>	Posttransplant patient and graft survival	Longer follow-up posttransplant and more complete survival information	Only patients presenting for LT
Yerdel et al., 2000 <sup>(96)</sup>	Anatomical and degree of occlusion	<ul style="list-style-type: none"> <li>&lt;50% occlusion</li> <li>&gt;50% occlusion</li> <li>Complete PV/SV occlusion</li> <li>Complete PV occlusion with SMV extension</li> </ul>	Posttransplant survival	Well-defined long-term posttransplant survival; investigation into pretransplant risk factors; more clinically pertinent anatomical definitions	Only patients presenting for LT
Charco et al., 2005 <sup>(97)</sup>	Anatomical and collateral presence	<ul style="list-style-type: none"> <li>Confined to PV</li> <li>Extending to proximal SMV</li> <li>Diffuse involvement of mesenteric system with large collaterals</li> <li>Diffuse with fine collaterals</li> </ul>	None based on this system	System based on collateral formation and surgical approach	Only patients presenting for LT; no outcome assessment of classification system
Bauer et al., 2006 <sup>(99)</sup>	Anatomical and degree of occlusion	<ul style="list-style-type: none"> <li>&lt;25% occlusion of PV</li> <li>26%-50% occlusion</li> <li>51%-75% occlusion</li> <li>76%-100% occlusion</li> <li>All stratified by location of clot and cavernous transformation presence</li> </ul>	Change in grade after TIPS placement	First series dedicated to patients not necessarily undergoing LT; extreme detail on clot location and percentage occlusion	No long-term outcome data and only patients who underwent TIPS and endovascular intervention
Ma et al., 2014 <sup>(100)</sup>	Anatomical; degree of occlusion; and presence of collaterals	<ul style="list-style-type: none"> <li>Duration of clot</li> <li>Presence of symptoms</li> <li>Degree of portal hypertension</li> </ul>	Correlation with symptoms and portal hypertension complications	Nontransplant cohort with careful imaging classification and symptom measurement	No long-term outcome assessment
Sarin et al., 2016 <sup>(101)</sup>	Anatomical; degree of occlusion; duration; and presence of underlying liver disease	<ul style="list-style-type: none"> <li>Location of clot</li> <li>Degree of occlusion</li> <li>Time course</li> <li>Extent of occlusion</li> <li>Presence of underlying liver disease</li> </ul>	None	PVT classified in multiple characteristics and scenarios	System is complex and nomenclature can be cumbersome; no outcome correlation.
Bhangui et al., 2019 <sup>(98)</sup>	Anatomical and presence of collaterals	<ul style="list-style-type: none"> <li>Complex</li> <li>Noncomplex</li> </ul>	Requirement of portal inflow reconstruction at the time of LT	Simplifies anatomical considerations for PV management during LT	Only applies to LT techniques; no natural history outcomes

Abbreviations: SMV, superior mesenteric vein; SV, splenic vein.

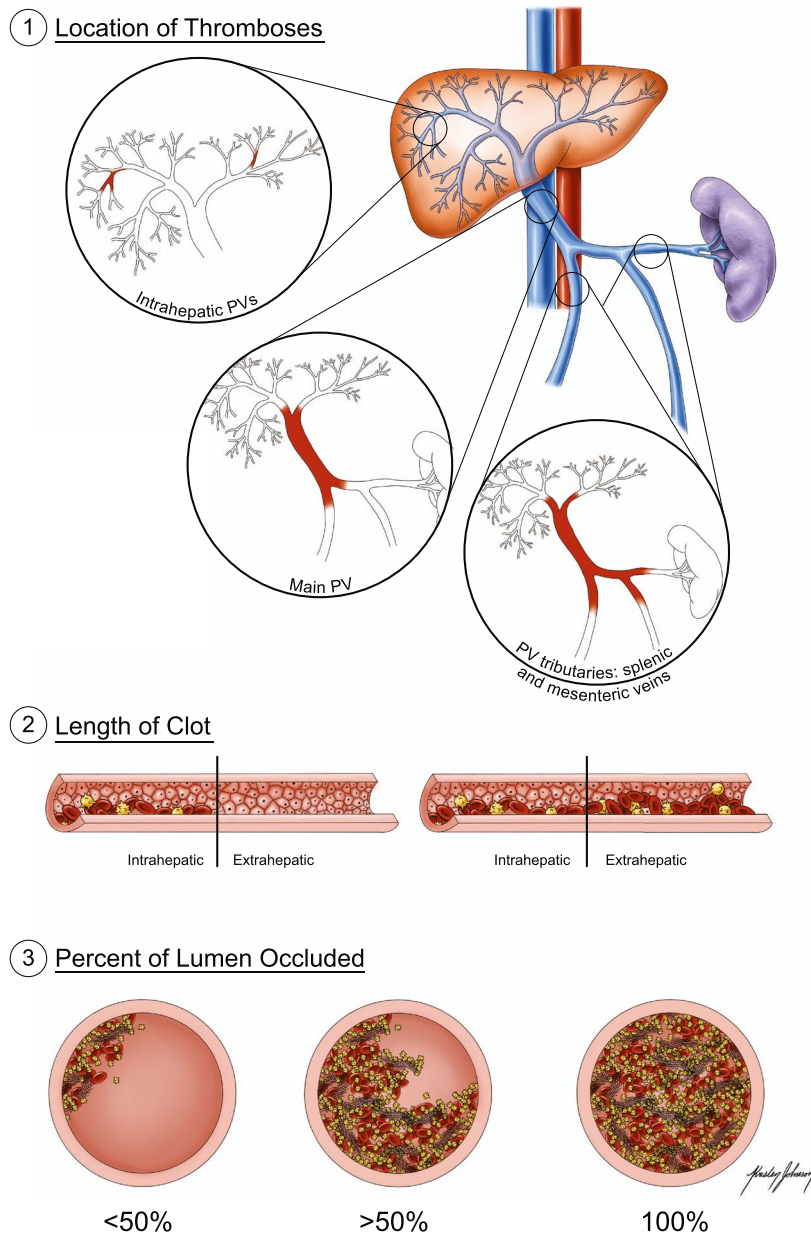


FIG. 3. The important components of PVT in clinical practice and research design.

are needed. Figure 3 depicts some of the important points to note when defining the location, extent, and percent occlusion of a PVT. When available, a morphometric assessment of residual portal venous lumen is desirable. Technologies for assessing total volume of clot burden should be developed and made clinically available, especially in the setting of treatment response assessment.<sup>(102,103)</sup>

## GUIDANCE STATEMENT

- In any patient with PVT, a standardized documentation of initial site, extent, degree of luminal obstruction, and chronicity of clot formation is recommended in order to make objective serial assessments of spontaneous regression or treatment response.



## PVT Prevalence and Risk Factors: Patients With Cirrhosis

Determining the incidence and prevalence of PVT is difficult because of the heterogeneity of risk factors in the population and lack of a universal classification system. As a result, the reported prevalence and incidence of PVT vary widely. The most studied cirrhosis population with regard to PVT is LT candidates. One report, based on 849 patients with cirrhosis who underwent LT with well-defined explant thrombosis classification, described a prevalence of 9% with either partial or complete obstruction of the main PV.<sup>(94)</sup> Another study from Japan showed autopsy PVT prevalence of 0.05% in patients without cirrhosis and 6.59% in patients with cirrhosis.<sup>(104)</sup> Recent reports, including national databases of hospital discharge and transplant registries, have listed prevalence rates in patients with cirrhosis between 1.3% and 9.8%.<sup>(96,105-110)</sup> Fewer prospective studies documenting incidence rates in the cirrhosis population have been published, but a prospective incidence ranging between 3.2% and 4.1% at 1 year after diagnosis with cirrhosis is often cited.<sup>(111-114)</sup>

Severity of portal hypertension and liver disease are major predictive factors for PVT in patients with cirrhosis.<sup>(113-118)</sup> Decreased velocity of PV flow at baseline has been recognized as a risk factor for PVT in patients with cirrhosis in several studies, albeit with varied predictive value.<sup>(117-120)</sup> Some studies have identified specific thresholds of portal flow associated with increased risk of PVT, ranging from 10 to 15 cm/s, as determined by Doppler ultrasonography.<sup>(117,119,121)</sup> A meta-analysis demonstrated an increased incidence in PVT in patients with cirrhosis taking non-selective beta-blockers (OR, 4.62; 95% CI, 2.50-8.53;  $P < 0.001$ ;  $I^2 = 80\%$ ;  $P < 0.001$ ).<sup>(122)</sup> However, analysis of confounding variables in this study attributable to the presence of esophageal varices, extent of portal hypertension, and nonselective beta-blocker use as secondary variceal bleeding prophylaxis has raised questions about the independent effect of the nonselective beta-blockers in development of PVT.<sup>(114,115,123)</sup> The potential role of an altered endothelium has been underinvestigated<sup>(124)</sup> and data on the role of inflammation/bacterial translocation are still limited.<sup>(107,125)</sup> Obesity, metabolic syndrome, and NASH cirrhosis are also recognized as independent risk factors for

PVT.<sup>(126-128)</sup> There are contrasting data on the prevalence of factor V Leiden and G20210A prothrombin gene mutation in this population, and testing for these disorders in the cirrhosis population is rarely useful and does not change management.<sup>(113,129)</sup> A detailed thrombophilia workup in the patient with cirrhosis is not generally recommended unless specific concerns are raised during the history, routine laboratory and imaging workup (Table 7). HCC invading the PV and/or HV is common in patients with cirrhosis; therefore, it is mandatory to rule out malignant venous obstruction with appropriate dynamic contrast-enhanced studies because the treatments and prognosis are vastly different compared to those with spontaneous bland thrombosis. Detailed reviews of imaging the portal system and the strengths and weaknesses of the various modalities are beyond the scope of this guidance document and are published elsewhere.<sup>(130-132)</sup>

## PVT Prevalence and Risk Factors: Patients Without Cirrhosis

PVT in patients without cirrhosis is a rare disease. An autopsy study from Japan showed a PVT prevalence of 0.05%,<sup>(104)</sup> but this study likely overestimated PVT prevalence in the general population due to of post mortem thrombosis. A combined evaluation by an experienced hematologist and hepatologist of every patient without cirrhosis who develops PVT is recommended. In the patient without cirrhosis, PVT and HVT share many common risk factors, and the thrombophilia workup is similar in both groups (Table 7). In contrast to the patient with cirrhosis, a detailed thrombophilia workup is warranted in most patients without cirrhosis who develop a PVT (Table 8).

Obstruction of the extrahepatic portal venous system in patients without cirrhosis is mostly related to myeloproliferative neoplasia, surgery, or inflammatory conditions affecting the digestive system organs or the spleen (Table 7).<sup>(1)</sup> Bariatric surgery, splenectomy, pancreatitis, inflammatory bowel disease, appendicitis, and diverticulitis are important contributors to extrahepatic portal venous obstruction as well, and ~30% of these patients also have a systemic thrombophilic disorder.<sup>(133)</sup> Among the inherited thrombophilias, the G20210A prothrombin gene mutation is most prevalent in this

TABLE 7. Prevalence and Risk Factors for Thrombosis of the HVs and PV in Patients Without Cirrhosis

	HVT/BCS		Extrahepatic PV Thrombosis	
Acquired hematological disorders				
Myeloproliferative neoplasia	Most common in Western patients. Frequently masked by hypersplenism. Splenomegaly nonspecific when portal hypertension is present. Significant positive predictive value of platelet count >200,000/ $\mu$ L together with splenomegaly >15 cm in a context of severe portal hypertension. Diagnosis based on first-line identification of JAK2 V617F mutation (86% of these) and CALR mutations (much less common) and, when negative, on bone marrow biopsy	41% <sup>(326-328)</sup>	Most common in Western and Asian patients. Frequently masked by hypersplenism. Splenomegaly nonspecific when portal hypertension is present. Significant positive predictive value of platelet count >200,000/ $\mu$ L together with splenomegaly >15 cm in a context of severe portal hypertension. Diagnosis based on first-line identification of JAK2 V617F mutation and CALR mutations (86% of these) and, when negative, on bone marrow biopsy	32% <sup>(326-328)</sup>
Antiphospholipid syndrome	Low diagnostic specificity of isolated anticardiolipin antibodies in a context of symptomatic liver disease	10% <sup>(329)</sup>	Less common than for large HVs and IVC	<sup>(329)</sup>
Paroxysmal nocturnal hemoglobinuria	Uncommon disease presentation	7% <sup>(330)</sup>	Rare presentation	NA
Inherited thrombophilia conditions				
Factor V Leiden	Over-represented in Western patients. Molecular diagnosis	8% population prevalence in Europeans <sup>(331-334)</sup>	Uncertain role. Molecular diagnosis	7% <sup>(331, 333, 335)</sup>
Factor II G20210A mutation	Uncertain role. Molecular diagnosis	3% population prevalence in Europeans <sup>(332-334)</sup>	Over-represented in Western patients. Molecular diagnosis	7% <sup>(333)</sup>
Protein C deficiency	Plasma activity nonspecific in the context of liver dysfunction. Molecular diagnosis of uncertain value attributable to multiple private mutations	5% <sup>(336)</sup>	Plasma activity nonspecific in the context of liver dysfunction. Molecular diagnosis of uncertain value attributable to multiple private mutations	6% <sup>(336)</sup>
Protein S deficiency	Plasma level nonspecific in a context of liver dysfunction. Molecular diagnosis of uncertain value attributable to multiple private mutations	4% <sup>(336)</sup>	Plasma level nonspecific in a context of liver dysfunction. Molecular diagnosis of uncertain value attributable to multiple private mutations	3% <sup>(336)</sup>
Antithrombin deficiency	Plasma activity nonspecific in the context of liver dysfunction. Molecular diagnosis of uncertain value attributable to multiple isolated mutations	1% <sup>(336)</sup>	Plasma activity nonspecific in the context of liver dysfunction. Molecular diagnosis of uncertain value attributable to multiple isolated mutations	4% <sup>(336)</sup>
Local factors and other systemic diseases of undetermined significance and prevalence				
Behcet's disease	Major cause in the Mediterranean region	2%-3% <sup>(337-340)</sup>	Uncommon	NA
Celiac disease	Over-represented in North Africa	1% <sup>(337)</sup>	Uncommon	NA
Obesity	Uncertain role	NA	Abdominal obesity over-represented	Bureau et al., 2016 <sup>(341)</sup>
Oral contraceptives or recent pregnancy	Over-represented in Western patients	23% <sup>(342)</sup>	Uncertain role	Janssen et al., 2001 <sup>(343)</sup>
Low socioeconomic status	Over-represented in Asian patients with obstructed IVC	Shrestha et al., 1996 <sup>(344)</sup>	Uncertain role	NA

TABLE 7. Continued

HVT/BCS		Extrahepatic PV Thrombosis	
General and iatrogenic factors	Hepatic surgery, blunt abdominal trauma, hepatic cysts, prolonged immobilization, extrahepatic solid-organ malignancy	1%-2% <sup>(133,198)</sup>	Splenectomy, hepatic or biliary surgery, sleeve gastrectomy pancreatitis, inflammatory bowel disease, appendicitis, diverticulitis, blunt abdominal trauma extrahepatic solid-organ malignancy
Other	> 1 risk factor No risk factors	19% <sup>(134,135)</sup> 24% <sup>(134,135)</sup>	NA NA

\*Percent of thrombosis patients positive for disorder when known.  
Abbreviations: CALR, calreticulin; JAK2, Janus kinase 2; NA, not applicable.

setting. Overall, risk factors are absent in up to 35% of patients. A combination of several low-level risk factors appears to be more common in patients without cirrhosis with PVT than expected in the general population.<sup>(134,135)</sup> Table 8 outlines the strengths and weaknesses of thrombophilia testing in this population.

GUIDANCE STATEMENTS

- In patients **with cirrhosis**, it is mandatory to rule out malignant venous obstruction attributable to HCC with appropriate contrast-enhanced imaging studies.
- In patients **with cirrhosis**, an extensive evaluation for thrombophilic conditions is not necessary unless family history or routine laboratory testing raises other concerns.
- In patients **without cirrhosis** who have thrombosis of the portal venous system without a clear provoking factor, a full investigation for myeloproliferative disorders or another thrombophilic condition is warranted, usually in consultation with a hematologist.

Influence of PVT on Mortality in Patients With Cirrhosis

The influence of PVT on cirrhosis disease progression and mortality is not fully elucidated. There is a clear association of PVT with more severe portal hypertension; however, the temporal relationship is difficult to discern.<sup>(108,136)</sup> Whether PVT is merely a manifestation of progressive disease or an actual cause of disease progression is still unknown, and the literature is contradictory. In a prospective, longitudinal study of 1,243 patients with cirrhosis followed over a mean of 47 months,<sup>(113)</sup> PVT was deemed to follow hepatic decompensation temporally as opposed to being an etiological factor and was not independently associated with disease progression. Other prospective studies have arrived at similar conclusions.<sup>(114,137)</sup> In contrast, a small, prospective, randomized controlled trial of enoxaparin compared to no anticoagulation therapy in prevention of PVT in high-risk patients with cirrhosis<sup>(125)</sup> showed not only efficacy in prevention of PVT in the enoxaparin group, but also a survival and decompensation benefit. Although this study has not been replicated, the implication of prolonging

**TABLE 8. Recommendations and Limitations of Specialty Testing for Thrombophilic Conditions**

Specialty Test*	Cohort to Be Tested	Limitations
JAK2 V617F mutation <sup>(328)</sup>	PVT/HVT in the absence of major provoking factor <sup>†</sup>	<ul style="list-style-type: none"> <li>Occult MPN is frequent; this test should be performed, even if CBC is not suggestive.</li> <li>If negative in the presence of thrombocytosis or clinical concern for polycythemia vera, further tests are needed to exclude an MPN.</li> </ul>
CALR mutation <sup>(327)</sup>	PVT/BCS in the absence of major provoking factor if JAK2 negative <sup>†</sup>	<ul style="list-style-type: none"> <li>Significant positive predictive value with platelet count &gt;200,000/μL together with splenomegaly &gt;15 cm in the context of severe portal hypertension</li> </ul>
Antiphospholipid antibodies <sup>(345,346)</sup> <ul style="list-style-type: none"> <li>Cardiolipin antibodies</li> <li>Beta2 glycoprotein antibodies</li> <li>Lupus anticoagulant</li> </ul>	PVT/BCS in the absence of major provoking factor <sup>†</sup>	<ul style="list-style-type: none"> <li>Solid-phase IgG and IgM anti-beta-2 glycoprotein-1 and anticardiolipin antibodies can be tested in the acute phase.</li> <li>Antibodies of potential clinical significance if &gt;40 GPL units or MPL units or &gt;99th percentile</li> <li>Diagnosis of antiphospholipid syndrome requires persistence of antibodies on repeat testing ≥12 weeks.</li> <li>Lupus anticoagulant should not be tested in the acute phase because acute changes and anticoagulation can interfere.</li> </ul>
Paroxysmal nocturnal hemoglobinuria flow cytometry <sup>(330)</sup>	PVT/BCS in the absence of major provoking factor <sup>†</sup>	<ul style="list-style-type: none"> <li>Increased index of suspicion if current/preexisting hemolytic anemia and/or cytopenias</li> <li>Extremely rare disease</li> </ul>
Heritable thrombophilia <ul style="list-style-type: none"> <li>Factor V Leiden</li> <li>Prothrombin gene polymorphism</li> <li>Protein C deficiency</li> <li>Protein S deficiency</li> <li>Antithrombin deficiency</li> </ul>	Not routinely recommended	<ul style="list-style-type: none"> <li>Results do not generally influence management.</li> <li>Proteins C, S, and antithrombin can be low in the context of acute thrombosis and/or liver disease and may not reflect an inherited deficiency.</li> </ul>

\*All tests are not necessarily indicated in all patients with PVT or HVT. Testing in this situation should be arranged in collaboration with a hematologist with a special interest in myeloproliferative neoplasia and thrombosis.

<sup>†</sup>Not required in those with recent major abdominal surgery/trauma or significant intra-abdominal inflammation and generally not required in those with preexisting cirrhosis.

Abbreviations: CBC, complete blood count; IGL, IgG phospholipid; MPL, IgM phospholipid; MPN, myeloproliferative neoplasia.

decompensation-free survival with prevention of PVT implies etiological potential. Anticoagulation therapy in this study was also associated with findings (decrease in bacterial translocation) believed to have hepatic benefits beyond prevention of PVT.

In relation to LT, there is a distinct technical advantage to maintaining a patent main PV in the recipient up to the time of surgery that is associated with improved posttransplant survival. Nonanatomical PV reconstructions during LT add technical difficulty and increase graft ischemic times. These technical complications add risk, and there are inferior survival and more complications in the LT recipient who presents for transplant with PVT.<sup>(138,139)</sup> In the United States, LT regulatory agencies have acknowledged this increased risk by incorporating the presence of pretransplant PVT as a strong independent predictive variable in models of posttransplant survival.<sup>(140)</sup> Large transplant database analyses and other case series confirm these findings.<sup>(94,96,108)</sup> However, it should be noted that these databases lack granularity to determine the size and extent of PVT, and therefore it is unknown whether there is a threshold

at which outcomes are worse. There are no randomized controlled trials of PVT therapy before transplant to determine whether regression of PVT before transplant improves posttransplant survival. Some researchers have suggested that PVT is again simply a measure of more advanced portal hypertension before transplant, and not an independent risk factor, in all but the extreme cases of extensive PV reconstruction.<sup>(96)</sup> Limited data suggest higher posttransplant vascular complication rates, including hepatic arterial thrombosis, in NASH patients with pretransplant PVT,<sup>(141)</sup> but this area needs further investigation.

## GUIDANCE STATEMENTS

- Outside of LT candidates, it is unknown whether PVT in an individual patient with cirrhosis is merely a reflection of progressive portal hypertension or independently causative of increased mortality.
- In LT recipients, the presence of PVT at the time of transplant is associated with increased posttransplant mortality.
- There are insufficient data to recommend



pretransplant treatment of PVT with the goal of improving posttransplant outcomes.

## Goals of Therapy and Rationale for Treatment: Patients With Cirrhosis

In patients with underlying cirrhosis and portal hypertension, congestive intestinal ischemia is much less frequent compared to patients without cirrhosis because of the presence of previously formed portosystemic collaterals. In the patient without ischemic symptoms, the aim of treatment is not to prevent portal hypertension development (that already exists), but to prevent worsening and avoid progression of thrombosis that may hinder a future LT. Management of complications of portal hypertension should be as recommended in other patients with cirrhosis.<sup>(142)</sup> In a small cohort of patients with PVT without cirrhosis, the incidence (7.4%) and severity of bleeding in patients in whom EVL was performed without stopping anticoagulation was not significantly different to that in patients who did not receive anticoagulants.<sup>(143)</sup> Similarly, one study in patients with cirrhosis suggests that LMWH continued through prophylactic EVL does not increase the risk of bleeding or death.<sup>(52)</sup> These results suggest that EVL can be performed without stopping anticoagulation, but more safety studies are needed to make a formal recommendation on this issue. Based on the available data, it seems unnecessary to delay anticoagulation until variceal eradication or adequate beta-blockade is achieved, and we recommend initiating these treatments as soon as possible. Figure 4 depicts the suggested management of occlusive or partially occlusive PVT in a patient with cirrhosis.

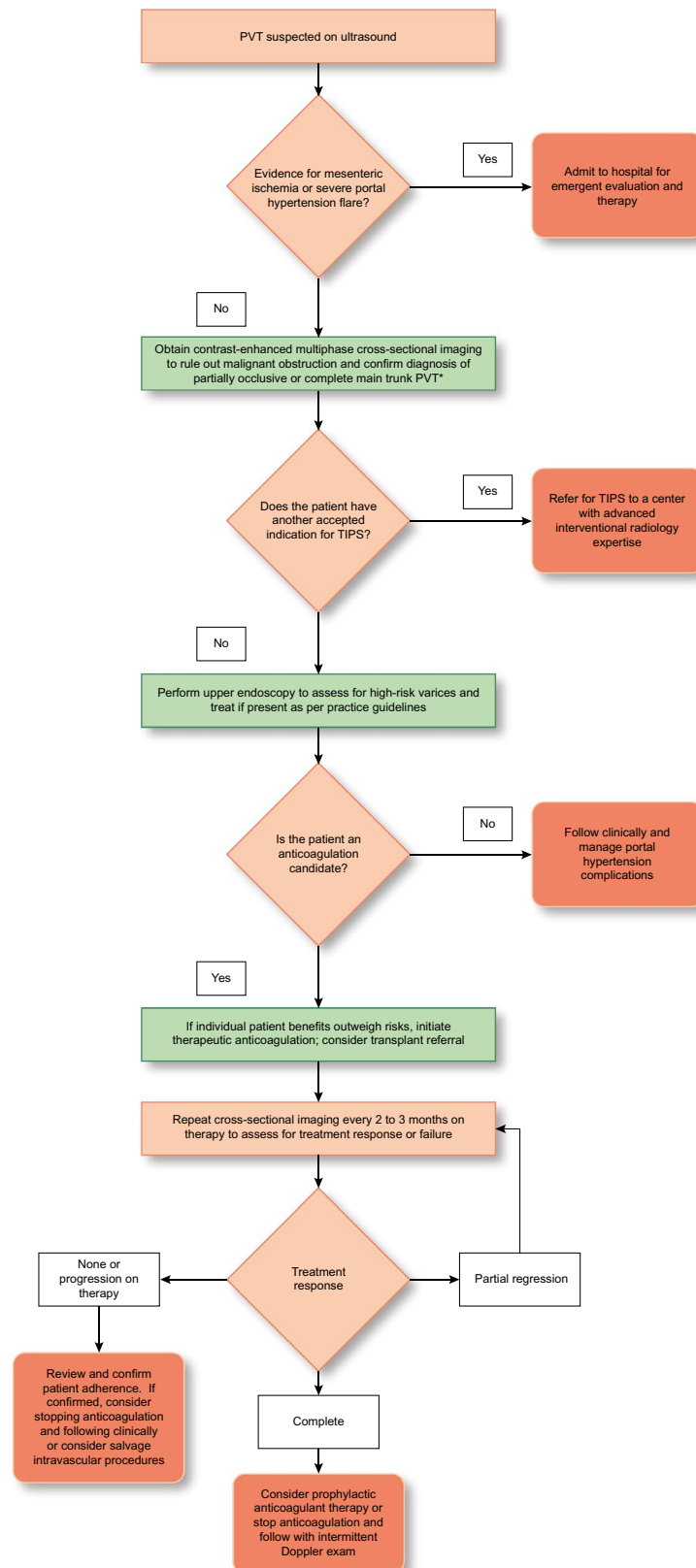
## Goals of Therapy and Rationale for Treatment: Patients Without Cirrhosis

In patients with an underlying healthy liver, the aims of therapy for recent PVT are to: (1) prevent thrombus extension to mesenteric veins; (2) prevent

complications of intestinal ischemia; and, ideally, (3) achieve recanalization to prevent development of portal hypertension. When present, portal hypertensive complications of PVT in patients without cirrhosis are managed in a similar fashion as those with cirrhosis. As mentioned above, the diagnosis of a thrombophilic condition or hematological malignancy is much more likely in the patient without cirrhosis, but this infrequently results in short-term management differences. If septic pylephlebitis is diagnosed, prolonged treatment with antibiotics adapted to the isolated bacteria or anaerobic digestive flora is necessary. Limited retrospective data suggest that patients with septic pylephlebitis also benefit from concurrent anticoagulant therapy, with higher complete resolution rates and lower long-term portal hypertension complications.<sup>(144)</sup>

## GUIDANCE STATEMENTS

- In all patients with recent PVT and concern for intestinal ischemia, immediate consultation with surgery, critical care, interventional radiology, and hematology is advised. Anticoagulation is essential, with the need for surgery in cases of intestinal infarction.
- In patients **without cirrhosis** and with recent PVT, directed antithrombotic therapy should be considered in order to avoid intestinal ischemia and prevent the development of chronic PVT with portal hypertension.
- In patients **with cirrhosis**, existing clinical trial data are weak regarding treatment indications for PVT without ischemic symptoms. Treatment should be considered on a case-by-case basis. Decisions for treatment of an individual patient should be based on expected benefit and minimization of clot extension risk that could potentially lead to progression of portal hypertension or hinder LT.
- In patients with cirrhosis who have recent thrombosis of small intrahepatic sub-branches of the PV or minimally occlusive (<50% obstruction of the lumen) thrombosis of the main PV, observation with serial imaging every 3 months without therapy is reasonable. Treatment for progressive clot should then be considered in this setting.
- In patients with cirrhosis with recent occlusive or partially occlusive (>50% obstruction of the lumen) thrombosis of the main PV or mesenteric veins,



**FIG. 4.** Suggested algorithm for management of recent partially occlusive (or totally occlusive) PVT not related to malignancy in patients with cirrhosis. <sup>a</sup>If minimally occlusive (<50% obstructed main PV lumen), serial imaging to assess for spontaneous regression in 2–3 months before intervention is reasonable. No directed therapy is recommended for cavernous transformation of the PV.

antithrombotic therapy should be considered to avoid thrombosis progression that may hinder a future LT or cause progression of portal hypertension.

- In patients with chronic complete occlusion of the main PV or cavernous transformation of the PV with established collaterals, there is no established benefit of anticoagulant or interventional therapy, and treatment should be targeted at management of portal hypertension complications.
- Data suggest that EVL can be performed safely without stopping therapeutic anticoagulation. Based on the available safety data, anticoagulation should be initiated as soon as possible and not delayed until variceal eradication or adequate beta-blockade is achieved.

## PVT Treatment Options

### THROMBOLYSIS AND INTERVENTIONAL VASCULAR PROCEDURES

Pharmacological thrombolysis (local or systemic) aimed to achieve recanalization has been proposed as an adjunct to anticoagulation in cases of recent PVT. However, significant procedure-related morbidity and mortality have been reported with recanalization rates similar to those achieved with anticoagulation alone.<sup>(145–147)</sup> Successful anecdotal cases combining transjugular thrombectomy, local fibrinolysis, and/or TIPS have been reported.<sup>(148–150)</sup>

In patients with chronic PVT, portal vein recanalization (PVR) followed by TIPS (TIPS-PVR) has been studied mostly in LT candidates to allow a physiological anastomosis between the graft and recipient PV.<sup>(151)</sup> In a small retrospective series, the trans-splenic approach to access the thrombosed PV was shown to be superior to the transhepatic approach, with a high success (60 of 61 patients) in achieving PVR and fewer side effects.<sup>(152)</sup> TIPS-PVR can also be considered in patients with advanced PVT and recurrent bleeding and/or refractory ascites not manageable medically or endoscopically. Although most studies describing TIPS-PVR have involved patients with cirrhosis, some patients without cirrhosis have also been studied.<sup>(153)</sup>

Some studies show good results performing PVR without the need for TIPS provided the PVT does not occlude the distal intrahepatic PV branches.<sup>(154,155)</sup>

More data are needed about the potential utility of TIPS-PVR in patients with chronic PVT.

### GUIDANCE STATEMENTS

- Local or systemic thrombolytic therapy should only be considered in very selected cases of recent PVT in whom intestinal ischemia persists despite anticoagulation.
- PVR followed by TIPS should be considered in LT candidates with chronic PVT that hinders a physiological anastomosis between the graft and recipient PV. This decision is made as part of a multidisciplinary management process, including surgical and interventional radiology expertise.
- PVR followed by TIPS should be considered in patients with chronic PVT and recurrent bleeding and/or refractory ascites not manageable medically or endoscopically.

## Medical Therapies for PVT

In patients with PVT, the choice of anticoagulation historically has been limited to UFH, LMWH, and VKAs, such as warfarin. With the advent of DOACs, clinicians face greater complexity of treatment decisions with more therapeutic options (Table 9).<sup>(156)</sup> Data remain considerably limited in this population; therefore, recommendations rely on smaller cohort studies and extrapolation from anticoagulation experience in other populations.<sup>(1,2,31,157–159)</sup>

## Medical Therapies: Patients With Cirrhosis

### TRADITIONAL ANTICOAGULANTS

Studies examining traditional anticoagulation in patients with cirrhosis and PVT vary in cohort characteristics, study design, treatment duration, and

TABLE 9. The Common Anticoagulants Available in the United States, Dosing Adjustments, and Treatment Considerations

VKAs		LMWH	Dabigatran	Apixaban	Betrixaban	Edoxaban	Rivaroxaban
Mechanism	Decreases factors II, VII, IX, X, PC, and PS, among others	Potentiates antithrombin (indirect inhibitor of IIa/Xa)	Inhibits factor IIa	Inhibits factor Xa	Inhibits factor Xa	Inhibits factor Xa	Inhibits factor Xa
Dosing	Variable daily; based on INR	Weight based; daily or BID	BID	BID	Once-daily	Once-daily	Once-daily
Elimination	Renal: 92% Hepatobiliary/intestinal: 8%	Renal: 40% Hepatobiliary/intestinal: 60%	Renal: 80% Hepatobiliary/intestinal: 20%	Renal: 27% Hepatobiliary/intestinal: 73%	Renal: 11% Hepatobiliary/intestinal: 85%	Renal: 50% Hepatobiliary/intestinal: 50%	Renal: 66% Hepatobiliary/intestinal: 34%
Initiation	Overlap with LMWH until INR > 2	See above	>5 days LMWH and then switch	10 mg BID for 7 days	160-mg loading dose	5 days LMWH and then switch	15 mg BID for 3 weeks
Standard dose	Overlap with LMWH until INR > 2	See above	150 mg BID	5 mg BID from day 8	80 mg daily	60 mg daily	20 mg daily from day 21
Dose reduction	NA	CrCl 15-30 mL/min and then reduce dose	110 mg BID for ≥80 years or concomitant verapamil, and consider for other high-risk groups	2.5 mg BID from 6 months	CrCl 15-30 mL/min and then reduce dose	30 mg daily for CrCl <50 mL/min or weight <60 kg	Consider dose reduction to 10 mg from 6 months.
INR monitoring	Yes	No	No	No	No	No	No
Liver disease labeling	All	All	Limited experience; no change in exposure in CTP B (n = 12)	Labeled for ≤CTP B without significant coagulopathy	Contraindicated in chronic liver disease	Contraindicated in chronic liver disease with coagulopathy; caution with mild/moderate liver disease, ALT/AST >2 × ULN or total bilirubin ≥1.5 × ULN	Contraindicated in liver disease with coagulopathy or bleeding risk, including CTP B/C
CKD adjustment	No	Yes, dose reduce for CrCl 15-30 mL/min Contraindicated with CrCl <15 mL/min	No	No	Yes, dose reduce for CrCl 15-30 mL/min Contraindicated with CrCl <15 mL/min	Yes, 30 mg for CrCl 15-50 mL/min Contraindicated with CrCl <15 mL/minute	No Contraindicated with CrCl <15 mL/min

Abbreviations: ALT, alanine aminotransferase; AST, aspartate aminotransferase; BID, twice-daily; CrCl, creatinine clearance; PC, protein C; PS, protein S; ULN, upper limit of normal.



endpoint definitions.<sup>(112,160-170)</sup> The majority of studies have examined the effect of LMWH and/or VKAs in patients with compensated cirrhosis without standardized endpoint definitions and varying treatment strategies. Bleeding outcomes are not standardized in this field, and therefore all comparative data assessments are subject to significant bias. Spontaneous recanalization has been observed in up to 40% of patients with cirrhosis who develop PVT, typically within 3 months.<sup>(113,171)</sup> A meta-analysis examined eight studies with treatment and no treatment comparator arms.<sup>(170)</sup> After excluding studies involving combined TIPS and anticoagulation, complete PVR occurred in 42% of patients with anticoagulation therapy alone and 13% of patients who did not receive anticoagulation or vascular intervention. A waiting period preceding initiating anticoagulation may be advised to allow for selection of patients with progressive or persistent PVT; however, studies demonstrate a relationship between recanalization and time to initiation of therapy, with <6 months being optimal, but shorter time periods have shown benefit as well.<sup>(164,168)</sup>

As discussed above, patients with cirrhosis who are candidates for LT may be treated with anticoagulation with the goal to recanalize the portal vascular system before LT.<sup>(112,169,172)</sup> However, because of the limitations of study design without controlling for spontaneous recanalization, it remains unclear which specific patients may benefit the most from therapy. Use of LMWH or VKAs in this setting is likely favored secondary to historical familiarity and available reversal strategies. However, there are significant limitations for LMWH and VKAs (Table 9). Given the need for factor replacement with FFP or prothrombin complex concentrates, emergency reversal at the time of transplant of these agents perioperatively risks volume overload or overcorrection to a hypercoagulable state, respectively.<sup>(172)</sup>

Outside of the context of LT, the benefits of anticoagulation for PVT are less clear.<sup>(113)</sup> Irrespective of this controversy, therapy with traditional anticoagulation likely promotes recanalization, which may benefit select patients, particularly those with associated portal hypertension symptoms.<sup>(170)</sup> The duration of therapy with traditional anticoagulation is unclear, and dosing is not standardized. Most important, the risk of anticoagulation remains undefined, but overall bleeding rates (unrelated to portal

hypertension) appear comparable to the population of patients without cirrhosis.<sup>(170)</sup> Similarly, a retrospective single-center study showed no increase in portal hypertensive bleeding in patients with cirrhosis taking VKAs compared to a similarly matched cohort of those not taking VKAs.<sup>(166)</sup> It does not appear that the presence of anticoagulation increases severity of bleeding or overall risk of mortality in patients who do develop gastrointestinal bleeding.<sup>(173)</sup>

## Direct Oral Anticoagulants

Patients with cirrhosis were excluded from clinical trials comparing DOACs versus VKAs and LMWH for prophylaxis and treatment of VTE or atrial fibrillation. Very little is known regarding the pharmacodynamics of DOACs in cirrhosis. *In vitro* studies conducted using plasma from patients with decompensated cirrhosis show differences in anticoagulant potency when measured by thrombin generation assay, and these findings have been confirmed *in vivo* using edoxaban.<sup>(174-177)</sup> These studies highlight concerns with these agents and emphasize the need for larger *in vivo* studies. Clinical experience with DOACs in patients with cirrhosis remains sparse and is generally limited to highly select cohorts with well-compensated cirrhosis.<sup>(156,178-181)</sup> Overall, DOACs appear to have a similar safety profile in patients with compensated cirrhosis compared to patients without cirrhosis, and their use is expanding in patients with all indications for anticoagulation, including atrial fibrillation, VTE, and PVT.<sup>(182,183)</sup> The availability of direct reversal agents may allay some fears concerning bleeding. For example, successful use of idarucizumab for reversal of dabigatran in a patient undergoing LT has been reported.<sup>(184)</sup> Two studies have directly compared DOACs to VKAs in different cohorts of patients with cirrhosis and PVT. One study involved 80 patients with recent PVT after elective splenectomy,<sup>(185)</sup> and the other involved 50 patients converted to oral therapy in a nonrandomized fashion after 2 weeks of injectable LMWH therapy.<sup>(186)</sup> Acknowledging the low level of evidence produced by both of these studies, bleeding rates were not significantly higher in patients treated with DOACs.

Future studies are needed in this population to establish the safety and efficacy of DOACs in patients with cirrhosis and PVT. Use of standardized

classification systems (Table 6) for PVT and standardized approaches to control for spontaneous recanalization will improve our understanding of anticoagulation in this population. Bleeding definitions are highly variable in these studies, and therefore use of validated and accepted bleeding definitions is also recommended.

## Medical Therapies: Patients Without Cirrhosis

### TRADITIONAL ANTICOAGULANTS

Studies examining the role of anticoagulation for PVT as the primary indication for therapeutic anticoagulation in this population are limited.<sup>(187-190)</sup> In 2010, a large prospective trial examining efficacy and safety of anticoagulation (LMWH, VKAs) in 95 consecutive patients with recent PVT without cirrhosis was published.<sup>(92)</sup> Anticoagulation was successful in 38% of the cohort, who achieved complete recanalization. Progression of thrombus with intestinal infarction occurred in 2 patients, and 9 patients developed bleeding on anticoagulation. Because portal hypertension is more common in this population, current recommendations suggest endoscopic evaluation to assess for and risk-stratify gastroesophageal varices in concert with anticoagulation therapy.<sup>(2)</sup>

Large international registry database analyses have examined the safety and efficacy of anticoagulation with traditional anticoagulants in this population.<sup>(191,192)</sup> Overall results indicate that patients with PVT who do not have cirrhosis are at higher risk of morbidity and mortality from thrombotic events and that the overall risk of bleeding from anticoagulation is low.

## Direct Oral Anticoagulants

The use of DOACs as therapy for PVT is now becoming commonplace despite the fact that large clinical trials of DOACs have excluded patients with PVT in the past.<sup>(193)</sup> Several retrospective, small studies are now published demonstrating the successful use of DOACs for this indication in patients

without cirrhosis.<sup>(94,194,195)</sup> A large, retrospective, single-center cohort examined 330 patients with PVT without cirrhosis treated with VKAs (*n* = 108), LMWH (*n* = 70), DOACs (*n* = 93), and no anticoagulation (*n* = 57).<sup>(196)</sup> In this cohort, DOAC therapy had superior efficacy (rates of thrombus resolution) and less major bleeding when compared to warfarin. DOAC use offers several advantages over warfarin, including the lack of a need for monitoring and predictable anticoagulant effect (Table 9). Although prospective studies are needed, the use of DOACs in this population will likely continue to expand, and careful analysis of outcomes requires multicenter collaboration and larger database registries. Specific features common to these patients, such as hematological malignancy, are important to consider when using DOACs, and consultation with hematology and hepatology experts in the field is advised.<sup>(197)</sup>

### GUIDANCE STATEMENTS

- The choice of agent for anticoagulant therapy (LMWH, VKAs, and DOACs) in PVT should be individualized. Consultation with a hematologist and/or expert hepatologist should be considered in deciding on anticoagulant agents and duration.
- Therapeutic anticoagulation in patients with cirrhosis appears to have similar non-portal hypertensive bleeding complication rates compared to the general population. Portal hypertension-related bleeding in patients with cirrhosis appears unchanged by the use of anticoagulants.
- DOACs are emerging as a common therapy for general medical patients with thrombosis. PVT data remain limited regarding safety and efficacy of these agents in patients with and without cirrhosis. In patients with cirrhosis, caution is advised in patients with advanced portal hypertension, and expert consultation is recommended.

## Hepatic Vein Thrombosis: Budd-Chiari Syndrome

HVT, or Budd-Chiari syndrome (BCS), is characterized by obstruction of the hepatic venous outflow anywhere from the small HVs to the junction

of the inferior vena cava (IVC) and the right atrium in the absence of intracardiac or pericardial obstruction.<sup>(134)</sup> This practice guidance refers to primary HVT/BCS, in which an endoluminal venous lesion (usually a thrombus or a vascular web) causes the obstruction.

## Prevalence and Etiology

Primary HVT/BCS is a rare disease mainly affecting young people (median age of 46 years) with a reported incidence below 1 case per million person-years (range, 0.17–0.88) and a prevalence of 1.40–7.69 per million.<sup>(198)</sup> An underlying prothrombotic disorder can be found in ~75% of patients with BCS, and more than one prothrombotic condition can be identified in at least 35% of patients (Table 7). No risk factors are found in 15%–30% of patients.<sup>(134,135)</sup> In Chinese HVT/BCS patients, the underlying etiology differs whether there is an isolated hepatic venous type, an isolated IVC type, or a combined type. In these two latter cases, there is a low prevalence of prothrombotic disorders, and most cases are associated with a low socioeconomic status and assumed to be triggered by abdominal infections.<sup>(199,200)</sup>

## Clinical Presentation and Diagnostic Considerations

Presentation varies from asymptomatic cases incidentally discovered on imaging obtained for other indications to acute liver failure, depending on the extent and rapidity of vein obstruction and the development of decompressive venous collaterals. Abdominal pain (61%), hepatomegaly (67%), and ascites (83%) are the most frequent symptoms at diagnosis,<sup>(134)</sup> and esophageal varices can be detected in >50% of patients.<sup>(134)</sup> Acute liver failure may arise if thrombosis is extensive and rapidly formed. Conversely, ~15%–20% of patients<sup>(134,201)</sup> are asymptomatic and incidentally diagnosed. Usually, these cases represent patients with partial thrombosis accompanied by the formation of decompressive venous collaterals with frequent atrophy of the affected liver and hypertrophy of those segments, which are well drained.<sup>(134,201,202)</sup> Severe acute

manifestations can appear in patients with imaging signs of chronic liver disease, which likely reflects recurrence of thrombosis in a previously unrecognized patient with HV occlusion. Typical laboratory findings are bilirubin and aminotransferase elevations with increase in PT in severe cases. Ascites analysis typically shows high protein content.<sup>(134)</sup>

In cases with obstruction of the IVC, either by thrombosis or compression by a hypertrophied caudate lobe, abdominal varices, lower limb edema, or ulcers are a frequent manifestation.<sup>(200)</sup> Around 40% of patients with HVT/BCS develop nodular liver lesions during follow-up, likely as a result of the vascular changes induced by the HVT/BCS.<sup>(203)</sup> Although these are usually benign regenerative nodules representing nodular regenerative hyperplasia, hepatocellular adenomas<sup>(204)</sup> and HCC<sup>(205)</sup> may also develop. Benign lesions are usually multiple (>10 lesions), small in size (<4 cm), hypervascular, and disseminated throughout the liver.<sup>(203)</sup> In one study from France, the cumulative incidence of HCC was 6% at 7 years of follow-up.<sup>(205)</sup> Patients with long-term IVC obstruction seem to have a higher risk for developing HCC.<sup>(205,206)</sup> HCC diagnosis in HVT/BCS is a challenge and must always rely on histology for diagnosis. A level of alpha-fetoprotein >15 ng/mL has been suggested as a predictive biomarker for HCC in HVT/BCS patients<sup>(205,207)</sup>; however, this threshold cannot be recommended in clinical practice until validated in larger studies. Although specific data are lacking, surveillance for HCC in patients with chronic HVT/BCS with ultrasound with or without alpha-fetoprotein levels every 6 months is recommended. Suspicious lesions should escalate to contrast-enhanced cross-sectional imaging and/or biopsy if the nature of the lesion is not certain based on imaging characteristics.<sup>(203)</sup> It should be noted that the widely adopted Liver Reporting and Data System (LI-RADS) criteria for CT/MR<sup>(208)</sup> interpretation of liver lesions specifically exclude patients with HVT/BCS and should not be applied to this population because the altered vascular perfusion of the liver leads to arterially perfused lesions, which often are not HCC.

Clinical manifestations of HVT/BCS are heterogeneous, justifying suspicion in any patient with acute or chronic liver disease of unknown origin and/or with an underlying prothrombotic condition. A thrombophilia workup is generally required in these patients, and consultation with a hematologist is warranted



(Table 8). The diagnosis requires demonstration of hepatic venous flow obstruction, and noninvasive imaging techniques (Doppler ultrasonography, CT, or MR) are the mainstay of diagnosis. Doppler ultrasound, performed by an experienced operator, has a sensitivity >75%.<sup>(209)</sup> Typical ultrasound features of venous obstruction are identification of thrombus, nonvisualization of the HV, collateral veins and transformation of the HV into a cord lacking flow signals, caudate lobe hypertrophy, and a caudate vein >3 mm in diameter. Usually, the role of contrast-enhanced MR or CT is for diagnosis confirmation and is the diagnostic study of choice in the absence of an experienced ultrasound operator. CT and MR can additionally depict rapid clearance of contrast from the caudate lobe and patchy hepatic enhancement attributable to uneven portal perfusion. Hepatic venography may be helpful in cases of uncertain diagnosis, and the most typical sign is the presence of a “spider web” pattern of collateral circulation. Liver biopsy is not necessary for diagnosis unless there is concern for small intrahepatic vein obstruction when histology is the only way to achieve definitive diagnosis.

## Treatment Options

The goals of HVT/BCS treatment include management of portal hypertension, treatment of the underlying thrombotic or malignant disease, and restoration of hepatic venous outflow. The most recommended and supported treatment approach is a progressive therapeutic strategy,<sup>(201,210)</sup> stepping from less invasive (medical) to more invasive (LT) treatment according to the clinical response. A major challenge is recognizing the appropriate time to step up to the next treatment choice in a given patient. Because of this difficulty, these patients should routinely be managed in tertiary referral centers.

## Medical Therapies

Medical treatment must be initiated early in the course and include treatment of the complications of portal hypertension. In addition to therapeutic anticoagulation, early recognition and treatment of an underlying prothrombotic disorder is also critical. All patients with HVT/BCS, even in the absence of a

recognized prothrombotic disorder, should receive anticoagulation with the aim of achieving recanalization and preventing thrombosis progression. Immediate LMWH, followed by a VKA, is the most frequent anticoagulation approach. Long-term UFH should be avoided because of the risk of heparin-induced thrombocytopenia.<sup>(210)</sup> Although promising and clinically attractive, data with DOACs are very limited.<sup>(178)</sup> One quarter of HVT/BCS patients will be alive at 5 years with medical therapy alone.<sup>(201)</sup>

## Interventional Vascular Procedures

### THROMBOLYSIS

The experience of thrombolysis in HVT/BCS is limited. In selected cases of recent and incomplete thrombosis, local instillation of recombinant tPA, streptokinase, or urokinase, usually in combination with angioplasty/stenting, can restore venous outflow.<sup>(211)</sup> Known contraindications to thrombolytic therapy, as outlined in product package inserts, should be thoroughly investigated before consideration of this therapy.

### PERCUTANEOUS ANGIOPLASTY

In cases of segmental stenosis, either in the cranial part of the HV or suprahepatic IVC,<sup>(212,213)</sup> percutaneous transluminal angioplasty with or without stenting may restore HV outflow. This presentation only accounts for ~10% of the cases in Western populations,<sup>(201)</sup> but segmental stenosis occurs in >80% of patients in China.<sup>(212,214)</sup> A single randomized controlled trial suggested that angioplasty plus routine stenting should be the first-line invasive therapy to treat short-length stenosis because this treatment is associated with a much lower incidence of restenosis than angioplasty alone.<sup>(215)</sup> However, the lack of survival difference and a high risk of selection bias in the population included in the study reduce the generalizability of this proposal, and therefore vein stenting should be reserved for angioplasty failures.<sup>(216)</sup> In addition, retrievable stents (retrieved after a median of 15 days) have also been proposed as an alternate treatment. However, these results should be interpreted



cautiously because a significant number of retrievable stent patients exhibited acute stent thrombosis.<sup>(217)</sup>

## VASCULAR DECOMPRESSION TECHNIQUES

Some techniques aim to convert the portal system into an outflow tract in order to decompress the liver. Mesocaval shunt is preferred over portocaval side-to-side shunt because it is technically more straightforward to perform in the setting of caudate lobe hypertrophy.<sup>(218)</sup> In the setting of IVC obstruction/stenosis, an infrahepatic IVC pressure >20 mm Hg or a gradient between the IVC and right atrium of 15 mm Hg is predictive of inadequate shunt function.<sup>(219)</sup> In these cases, a mesoatrial shunt<sup>(219)</sup> or decompressing the IVC together along with the portal venous system through a meso-cavo-atrial shunt may be challenging alternatives.<sup>(220)</sup> Currently, surgical shunts have been almost completely replaced by TIPS. The use of polytetrafluoroethylene (PTFE)-covered stents in TIPS should be placed in centers of expertise because of the technical difficulty in HVT/BCS patients. Indeed, in >40% of patients, a direct puncture from the IVC to the right PV is required, also known as direct intrahepatic portosystemic shunt (DIPS).<sup>(221)</sup> In a large cohort of patients with HVT/BCS unresponsive to medical therapy and treated with TIPS, 5-year transplant-free survival was 72%.<sup>(201)</sup>

Placement of TIPS soon after symptomatic HVT/BCS diagnosis has been recently suggested.<sup>(222)</sup> However, most evidence suggests that a step-wise strategy is effective and safe, provided that patients are followed closely and TIPS is implemented soon after less invasive therapies yield no improvement. Recent data suggest that liver elastography measurements may be a good noninvasive test to monitor HVT/BCS evolution. Elastography values are very high because of liver congestion and begin to decrease as congestion improves. This has been evaluated after invasive techniques.<sup>(223,224)</sup> It is possible that this technology can also be used to monitor the response to medical treatment.

## LIVER TRANSPLANTATION

LT is usually reserved for HVT/BCS patients who fail the less invasive approaches outlined above, but may be the first step in patients with severe

acute hepatic failure. In this situation, TIPS should be considered while waiting for LT because it may potentially salvage patients with severe presentations. Approximately 7% of patients fail previous treatment steps and require LT, and 5-year survival rates are >70%.<sup>(221,225)</sup> Additionally, pretransplant TIPS did not worsen prognosis after LT in HVT/BCS patients.<sup>(221)</sup> Although evidence comes from a small series of cases, living donor LT may be a viable choice with acceptable survival rates (>70% at 5 years).<sup>(226)</sup> After LT, special care must be taken to ensure treatment of underlying prothrombotic disorders to avoid recurrent thrombosis in cases in which the prothrombotic condition is not cured with LT.<sup>(227)</sup>

## GUIDANCE STATEMENTS

- HVT-BCS should be considered in any patient with liver disease (recent or chronic) of unknown etiology. Suspicion should be even higher in a patient with a recognized prothrombotic disorder.
- Doppler ultrasound, performed by an experienced operator, is the first-line imaging study for HVT/BCS. MR or CT can be used for diagnosis confirmation and interventional planning.
- At the time of HVT/BCS diagnosis, a full thrombophilia workup is recommended, and even when one causal factor is identified, additional factors should be investigated. Consultation with a hematologist is recommended.
- Surveillance for HCC in patients with chronic HVT/BCS is recommended as in the general cirrhosis population, with ultrasound every 6 months with or without alpha-fetoprotein determination. Because of the perturbed vascularity of the liver, HCC diagnosis in these patients should not rely on imaging criteria alone and should require histological confirmation.
- A progressive “step-up” therapeutic strategy according to the clinical response from less to more invasive therapies is recommended for HVT/BCS. Early referral to tertiary care centers with expertise in this disorder is recommended.
- All patients with HVT/BCS, even in the absence of a recognized prothrombotic disorder, should receive therapeutic anticoagulation.
- TIPS or DIPS using PTFE-covered stents is the treatment of choice for HVT/BCS when medical therapy or angioplasty fail or are not feasible.

Surgical shunts should only be considered if TIPS/DIPS is not feasible or fails.

- LT is reserved for HVT/BCS patients in whom the medical and vascular interventional approaches fail. LT may be the first step in patients with acute liver failure. In this situation, TIPS/DIPS should be considered while waiting for transplant because it may improve liver function and potentially avoid the need for transplantation.

## Sinusoidal Obstruction Syndrome

Sinusoidal obstruction syndrome (SOS), formerly known as hepatic veno-occlusive disease, is a distinct and potentially lethal form of liver injury characterized by toxic/inflammatory damage to sinusoidal endothelial cells. In this syndrome, these cells undergo necrosis and extrusion into the sinusoids, resulting in partial or complete occlusion of small hepatic venules, and thus SOS is a postsinusoidal form of portal hypertension.<sup>(228)</sup> It occurs most commonly as a complication of myeloablative chemotherapy regimens (high-dose with or without total-body irradiation) used before hematopoietic stem cell transplantation (HSCT), particularly following allogeneic (as opposed to autologous) HSCT.<sup>(1)</sup> Chemotherapeutic agents known to cause SOS are alkylating agents (cyclophosphamide, busulfan, and melphalan) and the platinum complexes (oxaliplatin, carboplatin, and cisplatin). Thiopurines (azathioprine, mercaptopurine, and thioguanine) have also been implicated. Even though targeted therapy is less toxic, gemtuzumab and inotuzumab have been associated with SOS. Unrelated to HSCT and cancer chemotherapy, pyrrolizidine alkaloids found in plants or bushes from which tea is made or that contaminate seeds are well-documented causes of SOS.<sup>(229,230)</sup>

Development can be acute, presenting 1-3 weeks after exposure, with sudden onset of right upper quadrant pain, weight gain attributable to edema, hepatomegaly, and ascites.<sup>(231,232)</sup> Aminotransferase elevations can be marked with no or mild elevations of alkaline phosphatase, although some cases may present with jaundice. Standardized diagnostic criteria for SOS (Seattle criteria<sup>(233)</sup> and Baltimore

criteria<sup>(231)</sup>) have been established, but presentations can be atypical. Subacute SOS is a poorly defined syndrome and overlaps with portosinusoidal vascular disorder (PSVD) because it occurs months or even years after exposure and presents with fatigue, ascites, hepatic encephalopathy, or varices, and symptoms may be attributable to nodular regenerative hyperplasia.<sup>(228)</sup> This most commonly occurs with chronic low-dose ingestion of pyrrolizidine alkaloids or oral chemotherapeutic agents.

Definitive diagnosis is histological, but performing a liver biopsy is challenging in these patients because of cytopenias and other comorbidities at the time the diagnosis is in question, especially in the HSCT population. Early-stage SOS is characterized by sinusoidal dilatation with red blood cells escaping through the space of Disse as well as perivenular necrosis. Later-stage SOS shows fibrous obliteration of central venules. In cases in which the diagnosis is uncertain, a transjugular liver biopsy with hepatic venous pressure gradient (HVPG) measurement should be performed. In the proper clinical scenario, clinically significant portal hypertension (HVPG  $\geq 10$  mm Hg) without an alternative cause is highly specific to rule in SOS.<sup>(234)</sup> The overall mortality rate from SOS averages ~5%, but depends on the severity of disease; in mild presentations (8% of cases), mortality is 1%; in cases that resolve with therapy (64%), mortality is 18%; and in severe cases (28%), mortality can be as high as 67%.<sup>(235)</sup>

Given its potential high mortality rate, early identification of high-risk patients (e.g., allogeneic HSCT, preexisting liver disease, or second HSCT) is critical. Data are sparse regarding preexisting liver disease as a risk factor for SOS because HSCT is uncommonly performed in patients with significant preexisting liver disease. A small study showed that any previous liver disease independently increased the risk for SOS (OR, 3.35; 95% CI, 1.71-6.58;  $P < 0.001$ ).<sup>(236)</sup> Preventive strategies are unproven, not specifically data driven, and usually based on local practices or expert opinion.<sup>(237)</sup> However, adjusting the conditioning regimen may reduce SOS risk, and the frequency of SOS has decreased over recent years partially because of the use of less aggressive myeloablative regimens (e.g., no cyclophosphamide, lower radiation doses).<sup>(236)</sup> Myeloablative regimens are strongly discouraged in patients with cirrhosis,<sup>(237)</sup> and before HSCT, workup should focus on excluding cirrhosis. Liver biopsy may

be needed for this purpose before HSCT, if feasible. Data on liver stiffness measurement and general hepatic outcomes following HSCT are sparse,<sup>(238,239)</sup> and correlation of liver stiffness with specific risk of SOS is limited to a small case series.<sup>(240)</sup> Care should be taken in the interpretation of liver stiffness measurements because of potential confounding from liver involvement of hematological malignancy or secondary iron overload, both of which can elevate liver stiffness.

Data from randomized controlled trials regarding ursodeoxycholic acid for prophylaxis of SOS have been mixed, with some studies showing benefits and others none<sup>(241-244)</sup>; however, a meta-analysis of pooled study results suggested an overall benefit (pooled relative risk, 0.34; 95% CI, 0.17-0.66).<sup>(245)</sup> Thus, ursodeoxycholic acid is recommended as prophylactic therapy for SOS in patients undergoing allogeneic HSCT.<sup>(244,246,247)</sup> The suggested dose is 12 mg/kg divided in two doses starting the day before conditioning and continuing for 3 months after HSCT.

Defibrotide is the only FDA-approved treatment for SOS and is generally reserved for moderate or severe cases.<sup>(246-248)</sup> In the past, some authorities have recommended it for prophylaxis in high-risk cases, but the benefit of this approach is unproven, and the acquisition costs for the drug are very high. Its mechanism of action is uncertain, but it has both anti-inflammatory and anticoagulant activities, although bleeding complications are uncommon. Defibrotide is recommended at a dose of 25 mg/kg/d for at least 21 days and until resolution of the SOS. Side effects are not different than best supportive care in large clinical trials.<sup>(248)</sup> Management of ascites and fluid retention in SOS is the same as for patients with cirrhosis. TIPS has been performed for treatment failures, published in case reports or very small case series, with some success in portal decompression, but no impact on overall survival.<sup>(249)</sup>

## GUIDANCE STATEMENTS

- SOS should be considered in patients in the appropriate clinical setting, typically 1-3 weeks after HSCT, with onset of right upper quadrant pain, weight gain attributable to edema, hepatomegaly, and ascites.
- Ursodeoxycholic acid is recommended as prophylactic therapy for SOS in all patients undergoing

allogeneic HSCT. The suggested dose is 12 mg/kg divided in two doses starting the day before conditioning and continuing for 3 months after HSCT.

- Defibrotide is the only FDA-approved treatment for SOS and is recommended for treatment of moderate-to-severe SOS. The benefit in prophylaxis in high-risk cases is not established.
- TIPS is unproven in SOS and cannot be recommended for this indication based on available evidence.

## Liver Vascular Malformations and Hereditary Hemorrhagic Telangiectasia

Hereditary hemorrhagic telangiectasia (HHT), or Osler-Weber-Rendu disease, is a rare (1 in 5,000-8,000 persons) autosomal-dominant genetic disease characterized by widespread arteriovenous malformations (macroscopic and microscopic) that can involve the skin, mucous membranes (oral, nasal, and conjunctival), lungs, brain, gastrointestinal tract, and/or liver. Because HHT is inherited in an autosomal-dominant pattern, a family history of recurrent bleeding in any of the target organs may aid in the diagnosis. Liver vascular malformations (LVMs) are present in 40%-70% of patients with definite HHT, more commonly in those with a mutation in the activin receptor-like kinase type 1 gene.<sup>(250)</sup> Mortality is higher in patients with LVMs versus those without them. Symptoms from LVMs occur at a median of 90 months after imaging diagnosis and typically appear around age 30, occurring predominantly in females.<sup>(251)</sup> Symptoms result from three types of shunting within the liver: hepatic artery (HA) to HV, HA to PV, and PV to HV.<sup>(252)</sup> Shunting leads to different clinical presentations, the most common being high-output heart failure, followed by biliary ischemia, portal hypertension (ascites more common, variceal hemorrhage rarer), portosystemic encephalopathy, and intestinal ischemia<sup>(253)</sup> (Fig. 5). Symptoms may occur concurrently or transition from one presentation to another. LVMs can present with a nodular liver (nodular regenerative hyperplasia), varices, ascites, and splenomegaly, leading

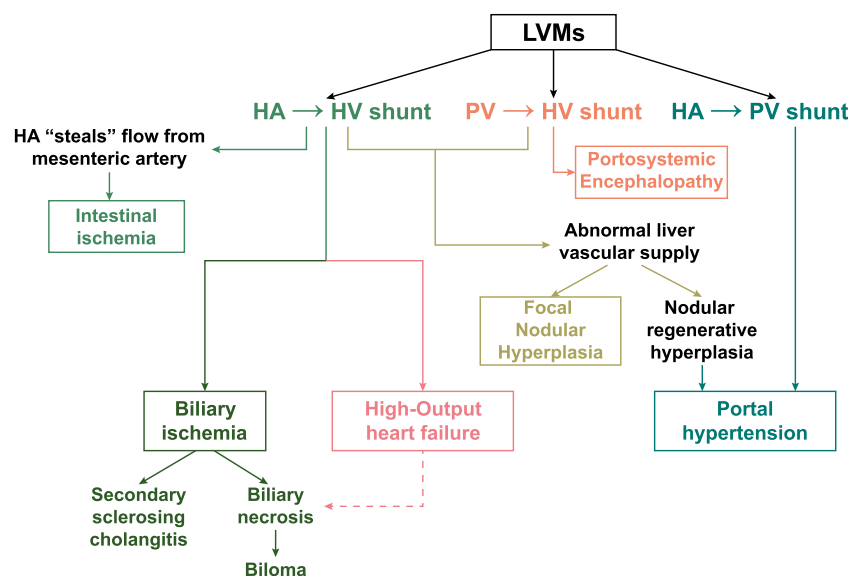


FIG. 5. Pathophysiology of the various clinical presentations of HHT.

to an erroneous diagnosis of cirrhosis. Liver synthetic function and platelet count are usually normal unless end-stage secondary biliary cirrhosis or severe hepatic congestion is present.<sup>(253)</sup> Prevalence of focal nodular hyperplasia is greater with LVMs (2.9%) than in the general population, and the liver may be nodular in the presence of LVMs. This may lead to the erroneous diagnosis of cirrhosis with HCC, neither of which is directly associated with HHT.<sup>(254)</sup> A liver biopsy is not recommended in patients with LVMs because findings are typically nonspecific, and bleeding risk may be substantial depending on the type of shunting.<sup>(255)</sup> Presence of LVMs should be confirmed by cross-sectional imaging showing heterogeneous enhancement or hypervascularization of the liver and common HA enlargement.

No treatment is recommended for asymptomatic LVMs.<sup>(255)</sup> Patients with symptomatic vascular malformations should be managed at specialized centers using a multidisciplinary approach. Standard therapy includes management of congestive heart failure, including correction of arrhythmias and anemia, which is frequent in these patients because of recurrent epistaxis or bleeding from gastrointestinal vascular malformations. Abdominal pain from biliary ischemia is managed symptomatically and/or with percutaneous drainage and antibiotics in the case of biloma infection; endoscopic retrograde

cholangiography should be avoided unless a clear dominant stricture amenable to therapy is present. Management of complications of portal hypertension should be the same as for cirrhosis. Symptoms are controlled with these therapies in >60% of patients.<sup>(251)</sup>

In nonresponders to standard therapy, several alternative treatments can be contemplated. The least invasive is the intravenous infusion of bevacizumab, a monoclonal antibody that inhibits the activity of vascular endothelial growth factor in endothelial cells, at a dose of 5 mg/kg intravenously every 2 weeks for six doses, with maintenance cycles in those with persistent or reappearing symptoms.<sup>(256,257)</sup> Bevacizumab improves epistaxis, cardiac index in heart failure patients, and ischemic cholangiopathy.<sup>(258,259)</sup> However, long-term efficacy and tolerance require further evaluation.<sup>(260)</sup> Hepatic arterial embolization or surgical ligation are only transiently effective and can be potentially harmful because they can lead to biliary and/or hepatic necrosis and are generally not recommended.<sup>(255)</sup> LT has been associated with 82.5% 10-year patient and graft survival in the largest European cohort<sup>(261)</sup> and 86% 4-year survival in a USA cohort.<sup>(262)</sup> However, a high rate of perioperative complications has been reported.<sup>(261)</sup> Additionally, LVMs may recur as soon as 6 years post-LT.<sup>(260,262,263)</sup>



## GUIDANCE STATEMENTS

- LVMs associated with HHT should be suspected in the presence of a liver bruit and a CT scan or MR with enlarged HA and heterogeneous enhancement of the liver, particularly in the setting of a family or personal history of recurrent nosebleeds, heart failure, unspecified liver disease, or brain hemorrhage.
- Asymptomatic LVMs do not warrant therapy or imaging surveillance.
- Management of symptomatic LVMs consists of standard therapy of specific complications, including heart failure, portal hypertension, and biliary ischemia.
- Symptomatic patients should be managed at a specialized center with a multidisciplinary team. In this setting, consideration for the use of bevacizumab and/or LT is warranted in nonresponders to standard therapy.

## Idiopathic Noncirrhotic Portal Hypertension

Idiopathic noncirrhotic portal hypertension (INCPH), or idiopathic portal hypertension, is characterized by portal hypertension in the absence of cirrhosis, PV obstruction, or HVT/BCS.<sup>(264,265)</sup> INCPH has been further characterized by the absence of sarcoidosis, congenital hepatic fibrosis, and schistosomiasis, all three conditions being well-documented causes of noncirrhotic portal hypertension. The precirrhotic stage of conditions that progress to cause cirrhosis (e.g., hepatitis B or C, fatty liver disease, or metabolic liver disease) have usually also been excluded from INCPH diagnostic criteria. This disorder is a heterogeneous collection of diseases of the liver, and the term INCPH is best considered as a broad category of diseases with similar manifestations.

## Histopathology

In addition to the absence of cirrhosis, various vascular histopathological lesions have been described in patients with INCPH, including intrahepatic PV stenosis (also called obliterative portal venopathy), nodular regenerative hyperplasia, or incomplete septal

cirrhosis, as well as less specific but suggestive histological alterations, such as herniated PVs, hypervascularized portal tracts, abnormal periportal vessels, sinusoidal dilatation, or regenerative hepatocytes.<sup>(266)</sup>

An overarching entity called portosinusoidal vascular disease (PSVD) has been proposed to account not only for INCPH, but also for the increasingly reported similar histopathological anomalies in patients without portal hypertension.<sup>(267-269)</sup>

## Diagnosis

INCPH should be considered in any patient with unexplained liver disease and portal hypertension with mild or no primary liver dysfunction. Furthermore, mild or no elevation of liver stiffness<sup>(270,271)</sup> or HVPG often contrasts with the clinical features of marked portal hypertension.

INCPH should be suspected when the conditions listed in Table 10 are present<sup>(269)</sup> along with clinical evidence of portal hypertension. Liver biopsy is required to exclude cirrhosis and is beneficial in the recognition of specific or suggestive lesions. Liver biopsy can be obtained through the transvenous route in patients with severe thrombocytopenia prohibiting the percutaneous route. The transvenous route offers the added benefit of allowing HVPG measurement, but percutaneous biopsy can effectively rule out cirrhosis and give diagnostic information as well. Reticulin stains on liver biopsy specimens are critical for assessing disorders of the liver architecture responsible for portal hypertension without cirrhosis.

## Associated Diseases and Etiology

Several uncommon systemic conditions (Table 10) appear to be unexpectedly more frequent in patients with INCPH.<sup>(269,272-276)</sup> These underlying conditions appear to bear prognostic significance and may require a specific management other than treatment related specifically to the portal hypertension. Therefore, a careful consideration of the conditions is recommended in light of medical history, clinical characteristics, imaging, and laboratory features.

**TABLE 10. Conditions Associated With INCPH and PSVD**

Blood diseases
Aplastic anemia
Myeloproliferative disorders
Hodgkin lymphoma
Multiple myeloma
Prothrombotic conditions
Protein C or S deficiency
Factor II G20210A or factor V Leiden gene mutation
Antiphospholipid syndrome
ADAMTS13 deficiency
Immunological/inflammatory disorders
Common variable immune deficiency
Autoimmune hepatitis
Systemic lupus erythematosus
Scleroderma
Rheumatoid arthritis
HIV infection
Celiac disease
Repeated gastrointestinal infections
Drug induced
Didanosine
Azathioprine
Thioguanine
Oxaliplatin
Genetic
HHT with liver vascular malformations
Turner syndrome
Adams-Oliver syndrome
TERT mutations
Cystic fibrosis
Familial cases of unknown genetic mutation

Abbreviations: ADAMTS13, a disintegrin and metalloproteinase thrombospondin type 1 motif 13; TERT, telomerase reverse transcriptase.

## Natural History and Outcome

Gastrointestinal bleeding related to portal hypertension is the most frequent and severe complication, much less frequently followed by ascites and portosystemic encephalopathy.<sup>(269,272–276)</sup> The latter two complications are most often triggered by bleeding and are transient in nature. Based on cross-sectional imaging, focal nodular hyperplasia-like lesions have been reported in 14% of patients.<sup>(277)</sup> However, hepatocellular adenoma and HCC are extremely rare. LT is needed in some patients, mostly because of

encephalopathy, refractory ascites, or shunting disorders such as hepatopulmonary syndrome.

The cumulative incidence of PVT in INCPH appears to be higher (32%) than in patients with cirrhosis (18%).<sup>(276)</sup> Risk factors have not been reproducibly recognized. Evidence implicating long-standing, well-controlled HIV infection or prothrombotic conditions needs replication. The independent effect of PVT on natural history is unclear in this disorder. The impact of INCPH on overall survival has been variably reported across surveys; however, a consistent finding has been low risk of liver-related death. Indeed, the associated conditions and general medical disorders appear to be the major determinants of overall survival.

## Therapy

There is no established independent therapy for INCPH or PSVD. There are no specific data on the treatment of established PVT in this setting, and it is unknown whether data for patients with cirrhosis or without underlying liver diseases are applicable. Similarly, there are no data on prophylaxis for gastrointestinal bleeding related to portal hypertension in INCPH. It is reasonable to expect a favorable risk-benefit balance in applying the recommendations for cirrhosis or chronic PVT to INCPH. A single retrospective series of these patients undergoing TIPS indicates that the main determinants of outcome are related to concurrent severe comorbidities, particularly renal dysfunction.<sup>(278)</sup>

## GUIDANCE STATEMENTS

- INCPH should be considered in any patient with evidence of portal hypertension but without cirrhosis or other known causes of noncirrhotic portal hypertension.
- Liver biopsy is required to exclude cirrhosis and may show specific histological changes. A reticulin stain may be helpful for histological diagnosis, and referral to specialized liver pathologists is recommended.
- In patients with INCPH, underlying risk factors for venous thrombosis, immune disorders, and inherited disorders known to be associated with this condition should be routinely considered.
- PVT may be more frequent in INCPH compared to patients with cirrhosis, but routine screening for PVT cannot be recommended based on available data. HCC is rare in this population.

## Hepatic and Splenic Artery Aneurysms

Hepatic (HAAs) and splenic artery (SA) aneurysms (SAAs) are uncommon.

True arterial aneurysms involve all three layers of the arterial wall, whereas pseudoaneurysms are characterized by a localized arterial wall disruption in which blood is confined by perivascular tissue, usually attributable to trauma or procedural complication. Unless otherwise specified, all commentary and guidance in this document is related to true aneurysms, not pseudoaneurysms.

### Hepatic Artery Aneurysms

Most HAAs are true arterial aneurysms.<sup>(279)</sup> The primary causes are atherosclerosis, mediointimal degeneration, trauma, and, less commonly, infection. Vasculitides (e.g., polyarteritis nodosa, systemic lupus erythematosus, Takayasu arteritis, and Kawasaki disease) and connective tissue disorders (e.g., Marfan syndrome, Ehlers-Danlos syndrome, and HHT) are rarely implicated.<sup>(279,280)</sup> Pseudoaneurysms are commonly intrahepatic and usually result from trauma related to a liver biopsy, transhepatic biliary drainage, cholecystectomy, hepatectomy, or LT.<sup>(280)</sup> Most true HAAs are asymptomatic and found incidentally on cross-sectional imaging obtained for other reasons. Patients may present with rupture into the biliary tract, with hemobilia, epigastric pain, and jaundice; rupture into the PV, with portal hypertension and variceal bleeding; or rupture into the peritoneal cavity, with abdominal pain and shock. The reported incidence of rupture in patients with true HAAs is up to 25%.<sup>(279-285)</sup> Such estimates are based on retrospective case series from clinical units and may be biased by a predominant inclusion of symptomatic patients. Large surveys in a general population are lacking. The mortality rate from rupture of an HAA is >30%.<sup>(279,280,284,285)</sup> Nonatherosclerotic aneurysms and multiple HAAs appear to carry an increased risk of rupture.<sup>(281)</sup> However, a published case series could not associate the risk of rupture of any individual HAA with its maximum diameter.<sup>(283)</sup>

Doppler ultrasound studies and CT readily demonstrate HAAs.<sup>(280,286,287)</sup> Multidetector CT

arteriography is the optimal tool for defining these lesions, assessing the collateral circulation, and planning treatment. In a retrospective review of 22 patients with a mean HAA diameter of 2.3 cm (range, 1.5–5.0) who were followed up and untreated for a mean of 68.4 months (range, 1–372), no complications were identified. Overall, open surgery and endovascular approaches have been proposed for elective management, but their comparison is not possible because of selection bias by indications. In addition, patients treated using endovascular approaches appear to have less morbidity and mortality.<sup>(280,282-285)</sup> The actual benefit-to-risk ratio of treating aneurysms deemed to be at higher risk of rupture has not been evaluated.<sup>(280,281,288)</sup> There are no data on which to base recommendations for surveillance of HAAs in the setting of expectant management.

### Splenic Artery Aneurysms

A majority of SAAs are true aneurysms of a mean size of ~3 cm upon diagnosis.<sup>(279,289)</sup> Female subjects account for ~70% of patients, and a positive relationship with multiparity has been suggested.<sup>(290-292)</sup> A majority of patients are in their sixth or seventh decade of life at the time of diagnosis.<sup>(290,293)</sup> Associations with pregnancy, portal hypertension, or pancreatitis have been frequently reported.<sup>(279,290-292,294,295)</sup> However, there is undoubtedly a detection bias in the published literature attributable to repeated abdominal imaging performed in such conditions.<sup>(290,294)</sup> Commonly reported causes include arteriosclerosis and fibromuscular dysplasia.<sup>(280,290)</sup> Recently, attention has been drawn to HHT<sup>(296)</sup> and the combination of alpha-1 antitrypsin deficiency and chronic liver disease requiring LT as risk factors.<sup>(297)</sup> Pseudoaneurysms of the SA are mostly related to pancreatitis, infection, and trauma.<sup>(289)</sup>

Most SAAs are asymptomatic and found incidentally.<sup>(290,292)</sup> Patients may present with penetration into the stomach with gastrointestinal bleeding or rupture into the peritoneal cavity with abdominal pain and shock. Incidence of rupture in patients with SAAs is ~3%, and mortality related to rupture is 20%–36%.<sup>(288,290,298,299)</sup> The risk of rupture of true aneurysms appears to be negligible, below a size of 2 cm, which is the size of the majority of SAAs upon detection.<sup>(288,290,298)</sup> Growth of SAAs with a diameter

of  $\leq 2$  cm is rare and, if present, typically develops very slowly,<sup>(290,300)</sup> suggesting that unusually large aneurysms may be attributable to a different yet unexplained pathophysiology.<sup>(301,302)</sup> The actual risk of rupture for aneurysms larger in diameter than 2 or 3 cm, although unknown, is likely  $<5\%$  after a mean observation duration of 70 months.<sup>(288,290,293)</sup> Data on the natural history of SAAs larger than 5 or 10 cm are lacking because interventional therapy has been proposed for nearly all such patients.<sup>(301,302)</sup> Risk factors for rupture are not clearly known.

Pregnancy has accounted for a high proportion of previously reported patients with rupture, suggesting that it could be a triggering factor, although a reporting bias cannot be ruled out.<sup>(291,292)</sup> With the advent of endovascular therapies, modern surveys of the natural history of SAAs in pregnancy are difficult to interpret because it has become standard practice to propose preemptive interventional management in affected women who plan pregnancy.<sup>(290-292,298,300)</sup> However, when a large obstetric population was evaluated, no statistical support was found for an increased risk of rupture during pregnancy.<sup>(303)</sup> The prevalence of SAAs in patients with portal hypertension with or without cirrhosis is  $\sim 15\%$ <sup>(304-308)</sup> and could be even higher when large portosystemic collaterals are present.<sup>(305,308)</sup> Whether LT is a specific risk factor for rupture in this population remains unclear<sup>(266,304,307)</sup> because the overall incidence (4%) is close to that in the general population.<sup>(307)</sup> It has been generally accepted that the risk of rupture and mortality is higher for pseudoaneurysms than for true aneurysms, likely attributable to the independent effect of causal conditions (pancreatitis, infection, or trauma).<sup>(289,307)</sup>

Open surgical repair, endovascular repair, and conservative management have been proposed, but prospective head-to-head comparisons are not available. A systematic review with meta-analysis attempted to account for the differences in the patient populations undergoing therapy.<sup>(293)</sup> In this pooled analysis, the proportion of patients treated for ruptured aneurysm was higher in the surgical than in the endovascular repair group (18.4% vs. 8.8%;  $P < 0.001$ ), respectively. In addition, 30-day mortality was higher (5.1% vs. 0.6%;  $P < 0.001$ ), but repeat intervention (0.5% vs. 3.2%) and minor complications were less common in the surgical repair group compared with the endovascular repair group, respectively. Comparison with the patients undergoing

conservative management is difficult because in the latter group, aneurysms were smaller in size and comorbidity was higher than in the other two groups. A subsequent report using a large data set demonstrated that endovascular repair was associated with lower postprocedural complication and infection rate, less resource utilization, and no difference in mortality compared to surgical treatments (3%;  $P = 0.99$ ).<sup>(309)</sup> A laparoscopic approach has also been proposed, but available data are still inconclusive as to the superiority of one surgical approach to another.<sup>(302)</sup> There has been no evaluation of the optimal modality and schedule for surveillance in patients with SAAs. There is no consensus on a size criterion requiring intervention on an asymptomatic true SAA,<sup>(288)</sup> but traditional surgical teaching based on case series suffering from significant selection bias has historically recommended intervention at 2 cm in size.<sup>(292)</sup> In adult living donor LT recipients, routine interventional therapy, regardless of size, has been proposed to prevent early posttransplant bleeding.<sup>(305)</sup> However, the low incidence of SAA rupture, the challenging surgical treatment, and risk of complications from endovascular therapy have led some to propose cautious recommendations to treat SAAs only when they are symptomatic,  $>30$  mm in size, or show enlargement during close follow-up with angiograms.<sup>(306)</sup>

## GUIDANCE STATEMENTS

- Doppler ultrasound or CT scan should be used for the detection of HAAs or SAAs and multidetector CT angiography for characterization and treatment planning.
- In patients with HAAs or SAAs, using a multidisciplinary approach, if an intervention is deemed necessary, endovascular repair should be considered first and, if inappropriate, open repair. These decisions should be made in consultation with vascular surgical and interventional radiology specialists.
- For recently diagnosed HAAs or SAAs of  $<2$  cm in size, early follow-up imaging (e.g., 3 and 12 months) should be performed to assess spontaneous growth rate. Any significant growth of an aneurysm on serial imaging should prompt consideration of intervention in consultation with other specialists.
- Urgent intervention should be considered for symptomatic or complicated HAAs or SAAs.



- In patients with pregnancy plans or LT candidates, elective interventions in patients with HAAs or SAAs should be considered. In other patients, intervention has not been proven superior to expectant management.

## Issues Specific to Children and Congenital Disorders

### EXTRAHEPATIC PORTAL VEIN OBSTRUCTION

Extrahepatic portal vein obstruction (EHPVO) has also been referred to as cavernous transformation of the PV in children. It is believed to be an acquired lesion subsequent to a number of postnatal events, including umbilical vein catheterization, omphalitis, and *de novo* thrombosis, attributable to hypercoagulable conditions. However, the embryology of the PV formation is complex, and at any one of a number of steps in PV formation, the final integrity of the PV may be compromised during development. The clinical hallmarks of EHPVO, as with any form of portal hypertension, are primarily those of hemorrhage from gastric and esophageal varices and hypersplenism with splenic enlargement, thrombocytopenia, and, less commonly, ascites. Liver function is always preserved unless EHPVO occurs with an accompanying coexistent primary liver disorder. Evidence suggests that early intervention with restoration of portal blood flow confers an advantage, and delayed reconstruction may be detrimental to the final outcome.<sup>(310)</sup> Treatment consists of management of the complications of portal hypertensive bleeding and consultation for possible shunt surgery. The meso-Rex bypass (surgical extrahilar mesenterico/left portal shunt<sup>(311)</sup>) has been established as the primary and preferred surgical correction for EHPVO, but portosystemic shunting with either a distal splenorenal shunt or a mesocaval shunt is indicated if the meso-Rex bypass is anatomically not possible.<sup>(312)</sup> The meso-Rex bypass corrects some of the physiological abnormalities subsequent to chronic portosystemic shunting, such as minimal hepatic encephalopathy and coagulation abnormalities.<sup>(313-315)</sup> Given the advancing confidence in the results of the meso-Rex bypass, it

has been proposed that corrective surgery should be considered in asymptomatic children to prevent the development of portal hypertension complications and downstream sequelae.<sup>(316)</sup> Evaluation and surgical treatment of these children should be in hospitals with expertise in hepatobiliary surgical care and transplantation in children.<sup>(316)</sup>

## Hepatic Hemangiomas

In recent years, there have been a number of changes in classification and treatment recommendations of hepatic hemangiomas in children.<sup>(317)</sup> These may be classified into two types: (1) congenital (rapidly involuting congenital hemangioma and noninvoluting congenital hemangioma) and (2) infantile (focal, diffuse, and multifocal). In general, the distinction between the congenital and infantile types of hemangiomas is blurred. Symptoms can range from none to cardiac decompensation attributable to high-output heart failure. The focal type rarely causes symptoms, and most can safely be observed. Many involute or remain stable. Hemangioma histopathological glutathione expression may occur in as many as 30%-50% of cases of infantile hemangiomata,<sup>(318)</sup> and these have been shown to respond to nonselective beta-blockers such as propranolol.<sup>(319,320)</sup> The multifocal or diffuse types may require interventions, ranging from medical therapies, such as beta-blockers or embolization, to surgical resection or LT in the most extreme examples. Other treatment depends primarily on symptoms and includes observation for many, medical therapies for heart-related symptoms, embolization, or hepatic arterial ligation as a means to reduce cardiac output, surgical resection for local or lobar disease, and LT primarily for those not responding to therapy or unresectable symptomatic cases.

## Hepatic Arteriovenous Malformations

Hepatic arteriovenous malformations are rare lesions that can be acquired or congenital. Acquired lesions are generally secondary to external trauma, such as a penetrating injury to the liver. Iatrogenic injuries may also be possible secondary to percutaneous liver

biopsies. Congenital fistulas lead to portal hypertension and reversal of flow in the PV, which may cause inflammatory changes in the gut drained by the portal venous system. Treatment options include embolization or resection of the anatomical sector of the liver that is involved with the vascular malformation.<sup>(321)</sup> Adjunctive medical therapies may include anti-inflammatory agents in the presence of rarely associated autoimmune disorders that coexist with hepatic arteriovenous malformations.<sup>(322)</sup>

## Congenital Portosystemic Shunts

Congenital extrahepatic portosystemic shunts were first described by Abernethy in the 18th century and were much later classified into type I and II lesions depending on the presence or absence of an accompanying hypoplastic PV. The largest cohort to date reports on 66 patients from multiple centers across Europe.<sup>(323)</sup> The hallmark of these shunts is hyperammonemia from shunting of mesenteric blood into the systemic circulation. Treatment with LT has been proposed, but is unnecessary in the vast majority of children because of modern endovascular shunt closure techniques.<sup>(324,325)</sup> A significant proportion of these patients may have severe congenital cardiac, genitourinary, and musculoskeletal defects.<sup>(323)</sup> Acquired portopulmonary hypertension (15% of cases) and hepatopulmonary syndrome (3%) require careful management<sup>(323)</sup> of pulmonary hypertension preoperatively and postoperatively.

## GUIDANCE STATEMENTS

- In children with congenital or acquired vascular diseases of the liver, early referral to centers with expertise in pediatric liver disease, hepatobiliary surgery, and LT is recommended.
- In children with EHPVO, evaluation for early intervention in the presymptomatic stage is recommended at a center with expertise in treating this disorder.
- Glutathione expression may occur in as many as 30%-50% of cases of infantile hemangiomas, and the use of beta-blockers such as propranolol is recommended in these patients.

**Acknowledgment:** We thank Lynee Sanders and Audrey Davis-Owino for their administrative support, Kristen M. Johnson for graphic arts and design, George Ioannou and David Goldberg for their patience and guidance, and the AASLD Practice Guidelines Committee for their attention to detail and constant support. Members of the AASLD Practice Guidelines Committee include George Ioannou (chair); Rabab Ali, Alfred Sidney Barritt IV, James R. Burton, Jr., Roniel Cabrera, Henry Chang, Michael F. Chang, Udem Ekong, Ruben Hernaez, Binu John, Patricia D. Jones, Patrick S. Kamath, David G. Koch, Cynthia Levy, Jeff McIntyre, Mindie H. Nguyen, Mary E.M. Rinella (board liaison), Lopa Mishra, (board liaison), Anjana A. Pillai, Daniel S. Pratt, David J. Reich, Barry Schlansky, Matthew J. Stotts, Amit G. Singal, Christopher J. Sonnenday, Lisa B. VanWagner, and Elizabeth C. Verna.

## REFERENCES

- 1) DeLeve LD, Valla DC, Garcia-Tsao G; American Association for the Study Liver Diseases. Vascular disorders of the liver. *HEPATOLOGY* 2009;49:1729-1764.
- 2) European Association for the Study of the Liver Diseases. EASL Clinical Practice Guidelines: vascular diseases of the liver. *J Hepatol* 2016;64:179-202.
- 3) Simonetto DA, Singal AK, Garcia-Tsao G, Caldwell SH, Ahn J, Kamath PS. ACG Clinical Guideline: disorders of the hepatic and mesenteric circulation. *Am J Gastroenterol* 2020;115:18-40.
- 4) Lisman T, Porte RJ. Pathogenesis, prevention, and management of bleeding and thrombosis in patients with liver diseases. *Res Pract Thromb Haemost* 2017;1:150-161.
- 5) Violi F, Basili S, Raparelli V, Chowdary P, Gatt A, Burroughs AK. Patients with liver cirrhosis suffer from primary haemostatic defects? Fact or fiction? *J Hepatol* 2011;55:1415-1427.
- 6) Lisman T, Bongers TN, Adelmeijer J, Janssen HL, de Maat MP, de Groot PG, et al. Elevated levels of von Willebrand Factor in cirrhosis support platelet adhesion despite reduced functional capacity. *HEPATOLOGY* 2006;44:53-61.
- 7) Bakker CM, Knot EA, Stibbe J, Wilson JH. Disseminated intravascular coagulation in liver cirrhosis. *J Hepatol* 1992;15:330-335.
- 8) Hugenholtz GC, Macrae F, Adelmeijer J, Dulfer S, Porte RJ, Lisman T, et al. Procoagulant changes in fibrin clot structure in patients with cirrhosis are associated with oxidative modifications of fibrinogen. *J Thromb Haemost* 2016;14:1054-1066.
- 9) Martinod K, Wagner DD. Thrombosis: tangled up in NETs. *Blood* 2014;123:2768-2776.
- 10) Weisel JW, Litvinov RI. Red blood cells: the forgotten player in hemostasis and thrombosis. *J Thromb Haemost* 2019;17:271-282.
- 11) Iba T, Levy JH. Derangement of the endothelial glycocalyx in sepsis. *J Thromb Haemost* 2019;17:283-294.
- 12) Shalaby S, Simioni P, Campello E, Spiezia L, Gavasso S, Bizzaro D, et al. Endothelial damage of the portal vein is associated with heparin-like effect in advanced stages of cirrhosis. *Thromb Haemost* 2020;120:1173-1181.

- 13) Zubairova LD, Nabiullina RM, Nagaswami C, Zuev YF, Mustafin IG, Litvinov RI, et al. Circulating microparticles alter formation, structure, and properties of fibrin clots. *Sci Rep* 2015;5:17611.
- 14) Tripodi A, Salerno F, Chantarangkul V, Clerici M, Cazzaniga M, Primignani M, et al. Evidence of normal thrombin generation in cirrhosis despite abnormal conventional coagulation tests. *HEPATOLOGY* 2005;41:553-558.
- 15) Lisman T, Leebeek FW, Mosnier LO, Bouma BN, Meijers JC, Janssen HL, et al. Thrombin-activatable fibrinolysis inhibitor deficiency in cirrhosis is not associated with increased plasma fibrinolysis. *Gastroenterology* 2001;121:131-139.
- 16) Blasi A, Patel VC, Adelmeijer J, Azarian S, Hernandez Tejero M, Calvo A, et al. Mixed fibrinolytic phenotypes in decompensated cirrhosis and acute-on-chronic liver failure with hypofibrinolysis in those with complications and poor survival. *HEPATOLOGY* 2020;71:1381-1390.
- 17) Davis JPE, Northup PG, Caldwell SH, Intagliata NM. Viscoelastic testing in liver disease. *Ann Hepatol* 2018;17:205-213.
- 18) De Pietri L, Bianchini M, Montalti R, De Maria N, Di Maira T, Begliomini B, et al. Thrombelastography-guided blood product use before invasive procedures in cirrhosis with severe coagulopathy: a randomized, controlled trial. *HEPATOLOGY* 2016;63:566-573.
- 19) Rocha LL, Neto AS, Pessoa CMS, Almeida MD, Juffermans NP, Crochemore T, et al. Comparison of three transfusion protocols prior to central venous catheterization in patients with cirrhosis: a randomized controlled trial. *J Thromb Haemost* 2020;18:560-570.
- 20) Rout G, Shalimar GD, Mahapatra SJ, Kedia S, Garg PK, Nayak B. Thromboelastography-guided blood product transfusion in cirrhosis patients with variceal bleeding: a randomized controlled trial. *J Clin Gastroenterol* 2020;54:255-262.
- 21) Vuyyuru SK, Singh AD, Gamanagatti SR, Rout G, Gunjan D, Shalimar. A randomized control trial of thromboelastography-guided transfusion in cirrhosis for high-risk invasive liver-related procedures. *Dig Dis Sci* 2020;65:2104-2111.
- 22) Kumar M, Ahmad J, Maiwall R, Choudhury A, Bajpai M, Mitra LG, et al. Thromboelastography-guided blood component use in patients with cirrhosis with nonvariceal bleeding: a randomized controlled trial. *HEPATOLOGY* 2020;71:235-246.
- 23) Lisman T. Interpreting hemostatic profiles assessed with viscoelastic tests in patients with cirrhosis. *J Clin Gastroenterol* 2020;54:389-391.
- 24) Northup P, Davis J. Shortcomings in design and analysis of clinical studies on bleeding and thrombosis in patients with cirrhosis. *Semin Thromb Hemost* 2020;46:665-672.
- 25) Lisman T, Porte RJ. Rebalanced hemostasis in patients with liver disease: evidence and clinical consequences. *Blood* 2010;116:878-885.
- 26) Baron TH, Kamath PS, McBane RD. Management of anti-thrombotic therapy in patients undergoing invasive procedures. *N Engl J Med* 2013;368:2113-2124.
- 27) Davidson JC, Rahim S, Hanks SE, Patel JJ, Tam AL, Walker TG, et al. Society of Interventional Radiology Consensus Guidelines for the periprocedural management of thrombotic and bleeding risk in patients undergoing percutaneous image-guided interventions-part I: review of anticoagulation agents and clinical considerations: endorsed by the Canadian Association for Interventional Radiology and the Cardiovascular and Interventional Radiological Society of Europe. *J Vasc Interv Radiol* 2019;30:1155-1167.
- 28) Patel JJ, Rahim S, Davidson JC, Hanks SE, Tam AL, Walker TG, et al. Society of Interventional Radiology Consensus Guidelines for the periprocedural management of thrombotic and bleeding risk in patients undergoing percutaneous image-guided interventions-part II: recommendations: endorsed by the Canadian Association for Interventional Radiology and the Cardiovascular and Interventional Radiological Society of Europe. *J Vasc Interv Radiol* 2019;30:1168-1184.e1.
- 29) ASGE Standards of Practice Committee; Acosta RD, Abraham NS, Chandrasekhara V, Chathadi KV, Early DS, Eloubeidi MA, et al. The management of antithrombotic agents for patients undergoing GI endoscopy. *Gastrointest Endosc* 2016;83:3-16.
- 30) Doherty JU, Gluckman TJ, Hucker WJ, Januzzi JL, Jr., Ortel TL, Saxonhouse SJ, et al. 2017 ACC Expert Consensus Decision Pathway for periprocedural management of anticoagulation in patients with nonvalvular atrial fibrillation: a report of the American College of Cardiology Clinical Expert Consensus Document Task Force. *J Am Coll Cardiol* 2017;69:871-898.
- 31) Intagliata NM, Argo CK, Stine JG, Lisman T, Caldwell SH, Viola F; Faculty of the 7th International Coagulation in Liver Diseases. Concepts and controversies in haemostasis and thrombosis associated with liver disease: Proceedings of the 7th International Coagulation in Liver Disease Conference. *Thromb Haemost* 2018;118:1491-1506.
- 32) Spyropoulos AC, Brohi K, Caprini J, Samama CM, Siegal D, Tafur A, et al. Scientific and Standardization Committee Communication: guidance document on the periprocedural management of patients on chronic oral anticoagulant therapy: recommendations for standardized reporting of procedural/surgical bleed risk and patient-specific thromboembolic risk. *J Thromb Haemost* 2019;17:1966-1972.
- 33) Giannini EG, Greco A, Marengo S, Andorno E, Valente U, Savarino V. Incidence of bleeding following invasive procedures in patients with thrombocytopenia and advanced liver disease. *Clin Gastroenterol Hepatol* 2010;8:899-902; quiz, e109.
- 34) Peck-Radosavljevic M, Simon K, Iacobellis A, Hassanein T, Kayali Z, Tran A, et al. Lusutrombopag for the treatment of thrombocytopenia in patients with chronic liver disease undergoing invasive procedures (L-PLUS 2). *HEPATOLOGY* 2019;70:1336-1348.
- 35) Terrault N, Chen YC, Izumi N, Kayali Z, Mitrut P, Tak WY, et al. Avatrombopag before procedures reduces need for platelet transfusion in patients with chronic liver disease and thrombocytopenia. *Gastroenterology* 2018;155:705-718.
- 36) Hibbert RM, Atwell TD, Lekah A, Patel MD, Carter RE, McDonald JS, et al. Safety of ultrasound-guided thoracentesis in patients with abnormal preprocedural coagulation parameters. *Chest* 2013;144:456-463.
- 37) Pillai AK, Andring B, Faulconer N, Reis SP, Xi Y, Iyamu I, et al. Utility of intravascular US-guided portal vein access during transjugular intrahepatic portosystemic shunt creation: retrospective comparison with conventional technique in 109 patients. *J Vasc Interv Radiol* 2016;27:1154-1159.
- 38) Medina JB, Andrade NS, de Paula Eduardo F, Bezinelli L, Franco JB, Gallottini M, et al. Bleeding during and after dental extractions in patients with liver cirrhosis. *Int J Oral Maxillofac Surg* 2018;47:1543-1549.
- 39) Perdigao JP, de Almeida PC, Rocha TD, Mota MR, Soares EC, Alves AP, et al. Postoperative bleeding after dental extraction in liver pretransplant patients. *J Oral Maxillofac Surg* 2012;70:e177-e184.
- 40) Stotts MJ, Lisman T, Intagliata NM. The spectrum of disease severity in cirrhosis and its implications for hemostasis. *Semin Thromb Hemost* 2020;46:716-723.
- 41) De Gottardi A, Thevenot T, Spahr L, Morard I, Bresson-Hadni S, Torres F, et al. Risk of complications after abdominal paracentesis in cirrhotic patients: a prospective study. *Clin Gastroenterol Hepatol* 2009;7:906-909.



- 42) Vieira da Rocha EC, D'Amico EA, Caldwell SH, Flores da Rocha TR, Soares ESCS, Dos Santos Bomfim V, et al. A prospective study of conventional and expanded coagulation indices in predicting ulcer bleeding after variceal band ligation. *Clin Gastroenterol Hepatol* 2009;7:988-993.
- 43) Nadim MK, Durand F, Kellum JA, Levitsky J, O'Leary JG, Karvellas CJ, et al. Management of the critically ill patient with cirrhosis: a multidisciplinary perspective. *J Hepatol* 2016;64:717-735.
- 44) Drolz A, Ferlitsch A, Fuhrmann V. Management of coagulopathy during bleeding and invasive procedures in patients with liver failure. *Visc Med* 2018;34:254-258.
- 45) Premkumar M, Saxena P, Rangegowda D, Baweja S, Mirza R, Jain P, et al. Coagulation failure is associated with bleeding events and clinical outcome during systemic inflammatory response and sepsis in acute-on-chronic liver failure: an observational cohort study. *Liver Int* 2019;39:694-704.
- 46) Fisher C, Patel VC, Stoy SH, Singanayagam A, Adelmeijer J, Wendon J, et al. Balanced haemostasis with both hypo- and hyper-coagulable features in critically ill patients with acute-on-chronic-liver failure. *J Crit Care* 2018;43:54-60.
- 47) Lin S, Wang M, Zhu Y, Dong J, Weng Z, Shao L, et al. Hemorrhagic complications following abdominal paracentesis in acute on chronic liver failure: a propensity score analysis. *Medicine (Baltimore)* 2015;94:e2225.
- 48) Intagliata NM, Davis JPE, Lafond J, Erdbruegger U, Greenberg CS, Northup PG, et al. Acute kidney injury is associated with low factor XIII in decompensated cirrhosis. *Dig Liver Dis* 2019;51:1409-1415.
- 49) Zanetto A, Rinder HM, Campello E, Saggiorato G, Deng Y, Ciarleglio M, et al. Acute kidney injury in decompensated cirrhosis is associated with both hypo- and hyper-coagulable features. *HEPATOLOGY* 2020 Jul 2. <https://doi.org/10.1002/hep.31443>. [Epub ahead of print]
- 50) Hung A, Garcia-Tsao G. Acute kidney injury, but not sepsis, is associated with higher procedure-related bleeding in patients with decompensated cirrhosis. *Liver Int* 2018;38:1437-1441.
- 51) Pache I, Bilodeau M. Severe haemorrhage following abdominal paracentesis for ascites in patients with liver disease. *Aliment Pharmacol Ther* 2005;21:525-529.
- 52) Bianchini M, Cavani G, Bonaccorso A, Turco L, Vizzutti F, Sartini A, et al. Low molecular weight heparin does not increase bleeding and mortality post-endoscopic variceal band ligation in cirrhotic patients. *Liver Int* 2018;38:1253-1262.
- 53) Shatzel J, Dulai PS, Harbin D, Cheung H, Reid TN, Kim J, et al. Safety and efficacy of pharmacological thromboprophylaxis for hospitalized patients with cirrhosis: a single-center retrospective cohort study. *J Thromb Haemost* 2015;13:1245-1253.
- 54) Puchalski JT, Argento AC, Murphy TE, Araujo KL, Pisani MA. The safety of thoracocentesis in patients with uncorrected bleeding risk. *Ann Am Thorac Soc* 2013;10:336-341.
- 55) Grabau CM, Crago SF, Hoff LK, Simon JA, Melton CA, Ott BJ, et al. Performance standards for therapeutic abdominal paracentesis. *HEPATOLOGY* 2004;40:484-488.
- 56) Runyon BA; AASLD. Introduction to the revised American Association for the Study of Liver Diseases practice guideline management of adult patients with ascites due to cirrhosis 2012. *HEPATOLOGY* 2013;57:1651-1653.
- 57) Drolz A, Schramm C, Seiz O, Groth S, Vettorazzi E, Horvatits T, et al. Risk factors associated with bleeding after prophylactic endoscopic variceal ligation in cirrhosis. *Endoscopy* 2020 Sep 7. <https://doi.org/10.1055/a-1214-5355>. [Epub ahead of print]
- 58) McGill DB, Rakela J, Zinsmeister AR, Ott BJ. A 21-year experience with major hemorrhage after percutaneous liver biopsy. *Gastroenterology* 1990;99:1396-1400.
- 59) Kalambokis G, Manousou P, Vibhakorn S, Marelli L, Cholongitas E, Senzolo M, et al. Transjugular liver biopsy—indications, adequacy, quality of specimens, and complications—a systematic review. *J Hepatol* 2007;47:284-294.
- 60) Rockey DC, Caldwell SH, Goodman ZD, Nelson RC, Smith AD; American Association for the Study of Liver Diseases. Liver biopsy. *HEPATOLOGY* 2009;49:1017-1044.
- 61) Seeff LB, Everson GT, Morgan TR, Curto TM, Lee WM, Ghany MG, et al. Complication rate of percutaneous liver biopsies among persons with advanced chronic liver disease in the HALT-C trial. *Clin Gastroenterol Hepatol* 2010;8:877-883.
- 62) Ewe K, Reinhardt P, Muller H, Ohler W. The bleeding time after liver biopsy does not correlate with peripheral coagulation factors. *Verh Dtsch Ges Inn Med* 1978;1060-1062.
- 63) Northup PG, Friedman LS, Kamath PS. AGA clinical practice update on surgical risk assessment and perioperative management in cirrhosis: expert review. *Clin Gastroenterol Hepatol* 2019;17:595-606.
- 64) de Boer MT, Christensen MC, Asmussen M, van der Hilst CS, Hendriks HG, Slooff MJ, et al. The impact of intraoperative transfusion of platelets and red blood cells on survival after liver transplantation. *Anesth Analg* 2008;106:32-44, table of contents.
- 65) Chee YL, Crawford JC, Watson HG, Greaves M. Guidelines on the assessment of bleeding risk prior to surgery or invasive procedures. *Br J Haematol* 2008;140:496-504.
- 66) Tripodi A, Chantarangkul V, Primignani M, Clerici M, Dell'era A, Aghemo A, et al. Thrombin generation in plasma from patients with cirrhosis supplemented with normal plasma: considerations on the efficacy of treatment with fresh-frozen plasma. *Intern Emerg Med* 2012;7:139-144.
- 67) Tripodi A, Primignani M, Chantarangkul V, Lemma L, Jovani M, Rebulla P, et al. Global hemostasis tests in patients with cirrhosis before and after prophylactic platelet transfusion. *Liver Int* 2013;33:362-367.
- 68) Kleinman S, Caulfield T, Chan P, Davenport R, McFarland J, McPhedran S, et al. Toward an understanding of transfusion-related acute lung injury: statement of a consensus panel. *Transfusion* 2004;44:1774-1789.
- 69) Basili S, Raparelli V, Napoleone L, Talerico G, Corazza GR, Perticone F, et al. Platelet count does not predict bleeding in cirrhotic patients: results from the PRO-LIVER study. *Am J Gastroenterol* 2018;113:368-375.
- 70) Napolitano G, Iacobellis A, Merla A, Niro G, Valvano MR, Terracciano F, et al. Bleeding after invasive procedures is rare and unpredicted by platelet counts in cirrhotic patients with thrombocytopenia. *Eur J Intern Med* 2017;38:79-82.
- 71) Drolz A, Horvatits T, Roedl K, Rutter K, Stauffer K, Kneidinger N, et al. Coagulation parameters and major bleeding in critically ill patients with cirrhosis. *HEPATOLOGY* 2016;64:556-568.
- 72) Afdhal NH, Giannini EG, Tayyab G, Mohsin A, Lee JW, Andriulli A, et al. Eltrombopag before procedures in patients with cirrhosis and thrombocytopenia. *N Engl J Med* 2012;367:716-724.
- 73) Stanca CM, Montazem AH, Lawal A, Zhang JX, Schiano TD. Intranasal desmopressin versus blood transfusion in cirrhotic patients with coagulopathy undergoing dental extraction: a randomized controlled trial. *J Oral Maxillofac Surg* 2010;68:138-143.
- 74) Arshad F, Stoof SCM, Leebeek FWG, Ruitenbeek K, Adelmeijer J, Blokzijl H, et al. Infusion of DDAVP does not improve primary hemostasis in patients with cirrhosis. *Liver Int* 2015;35:1809-1815.
- 75) Segal JB, Dzík WH; Transfusion Medicine/Hemostasis Clinical Trials Network. Paucity of studies to support that abnormal coagulation test results predict bleeding in the setting



- of invasive procedures: an evidence-based review. *Transfusion* 2005;45:1413-1425.
- 76) Townsend JC, Heard R, Powers ER, Reuben A. Usefulness of international normalized ratio to predict bleeding complications in patients with end-stage liver disease who undergo cardiac catheterization. *Am J Cardiol* 2012;110:1062-1065.
  - 77) Tripodi A, Mannucci PM. The coagulopathy of chronic liver disease. *N Engl J Med* 2011;365:147-156.
  - 78) Zimmon DS, Kessler RE. The portal pressure-blood volume relationship in cirrhosis. *Gut* 1974;15:99-101.
  - 79) Rassi AB, d'Amico EA, Tripodi A, da Rocha TRF, Migita BY, Ferreira CM, et al. Fresh frozen plasma transfusion in patients with cirrhosis and coagulopathy: effect on conventional coagulation tests and thrombomodulin-modified thrombin generation. *J Hepatol* 2020;72:85-94.
  - 80) Garcia-Tsao G, Abraldes JG, Berzigotti A, Bosch J. Portal hypertensive bleeding in cirrhosis: risk stratification, diagnosis, and management: 2016 practice guidance by the American Association for the study of liver diseases. *HEPATOLOGY* 2017;65:310-335.
  - 81) O'Leary JG, Greenberg CS, Patton HM, Caldwell SH. AGA clinical practice update: coagulation in cirrhosis. *Gastroenterology* 2019;157:34-43.e1.
  - 82) European Association for the Study of the Liver. EASL Clinical Practice Guidelines for the management of patients with decompensated cirrhosis. *J Hepatol* 2018;69:406-460.
  - 83) Bosch J, Thabut D, Albillos A, Carbonell N, Spicak J, Massard J, et al. Recombinant factor VIIa for variceal bleeding in patients with advanced cirrhosis: a randomized, controlled trial. *HEPATOLOGY* 2008;47:1604-1614.
  - 84) Mayer SA, Brun NC, Begtrup K, Broderick J, Davis S, Diringer MN, et al. Recombinant activated factor VII for acute intracerebral hemorrhage. *N Engl J Med* 2005;352:777-785.
  - 85) Arshad F, Ickx B, van Beem RT, Polak W, Grüne F, Nevens F, et al. Prothrombin complex concentrate in the reduction of blood loss during orthotopic liver transplantation: PROTON-trial. *BMC Surg* 2013;13:22.
  - 86) Kwon JO, MacLaren R. Comparison of fresh-frozen plasma, four-factor prothrombin complex concentrates, and recombinant factor VIIa to facilitate procedures in critically ill patients with coagulopathy from liver disease: a retrospective cohort study. *Pharmacotherapy* 2016;36:1047-1054.
  - 87) Giannini EG, Giambruno E, Brunacci M, Torres MCP, Furnari M, Bodini G, et al. Low fibrinogen levels are associated with bleeding after varices ligation in thrombocytopenic cirrhotic patients. *Ann Hepatol* 2018;17:830-835.
  - 88) Dempfle CE, Kalsch T, Elmas E, Suvajac N, Lucke T, Munch E, et al. Impact of fibrinogen concentration in severely ill patients on mechanical properties of whole blood clots. *Blood Coagul Fibrinolysis* 2008;19:765-770.
  - 89) Gunawan B, Runyon B. The efficacy and safety of epsilon-aminocaproic acid treatment in patients with cirrhosis and hyperfibrinolysis. *Aliment Pharmacol Ther* 2006;23:115-120.
  - 90) Engelen ET, Schutgens REG, Mauser-Bunschoten EP, van Es RJJ, van Galen KPM. Antifibrinolytic therapy for preventing oral bleeding in people on anticoagulants undergoing minor oral surgery or dental extractions. *Cochrane Database Syst Rev* 2018;7:CD012293.
  - 91) Roberts I, Shakur-Still H, Afolabi A, Akere A, Arribas M, Brenner A, et al. Effects of a high-dose 24-h infusion of tranexamic acid on death and thromboembolic events in patients with acute gastrointestinal bleeding (HALT-IT): an international randomised, double-blind, placebo-controlled trial. *The Lancet* 2020;395:1927-1936.
  - 92) Plessier A, Darwish-Murad S, Hernandez-Guerra M, Consigny Y, Fabris F, Trebicka J, et al. Acute portal vein thrombosis unrelated to cirrhosis: a prospective multicenter follow-up study. *HEPATOLOGY* 2010;51:210-218.
  - 93) Stieber AC, Zetti G, Todo S, Tzakakis AG, Fung JJ, Marino I, et al. The spectrum of portal vein thrombosis in liver transplantation. *Ann Surg* 1991;213:199-206.
  - 94) Nonami T, Yokoyama I, Iwatsuki S, Starzl TE. The incidence of portal vein thrombosis at liver transplantation. *HEPATOLOGY* 1992;16:1195-1198.
  - 95) Gayowski TJ, Marino IR, Doyle HR, Echeverri L, Micles L, Todo S, et al. A high incidence of native portal vein thrombosis in veterans undergoing liver transplantation. *J Surg Res* 1996;60:333-338.
  - 96) Yerdel MA, Gunson B, Mirza D, Karayalçin K, Olliff S, Buckels J, et al. Portal vein thrombosis in adults undergoing liver transplantation: risk factors, screening, management, and outcome. *Transplantation* 2000;69:1873-1881.
  - 97) Charco R, Fuster J, Fondevila C, Ferrer J, Mans E, Garcia-Valdecasas JC. Portal vein thrombosis in liver transplantation. *Transplant Proc* 2005;37:3904-3905.
  - 98) Bhangui P, Lim C, Levesque E, Salloum C, Lahat E, Feray C, et al. Novel classification of non-malignant portal vein thrombosis: a guide to surgical decision-making during liver transplantation. *J Hepatol* 2019;71:1038-1050.
  - 99) Bauer J, Johnson S, Durham J, Ludkowski M, Trotter J, Bak T, et al. The role of TIPS for portal vein patency in liver transplant patients with portal vein thrombosis. *Liver Transpl* 2006;12:1544-1551.
  - 100) Ma J, Yan Z, Luo J, Liu Q, Wang J, Qiu S. Rational classification of portal vein thrombosis and its clinical significance. *PLoS One* 2014;9:e112501.
  - 101) Sarin SK, Philips CA, Kamath PS, Choudhury A, Maruyama H, Nery FG, et al. Toward a comprehensive new classification of portal vein thrombosis in patients with cirrhosis. *Gastroenterology* 2016;151:574-577.e3.
  - 102) Luca A, Caruso S, Milazzo M, Marrone G, Mamone G, Crino F, et al. Natural course of extrahepatic nonmalignant partial portal vein thrombosis in patients with cirrhosis. *Radiology* 2012;265:124-132.
  - 103) Hidaka H, Kokubu S, Sato T, Katsushima S, Izumi N, Igura T, et al. Antithrombin III for portal vein thrombosis in patients with liver disease: a randomized, double-blind, controlled trial. *Hepatol Res* 2018;48:E107-E116.
  - 104) Okuda K, Ohnishi K, Kimura K, Matsutani S, Sumida M, Goto N, et al. Incidence of portal vein thrombosis in liver cirrhosis. An angiographic study in 708 patients. *Gastroenterology* 1985;89:279-286.
  - 105) Cagin YF, Atayan Y, Erdogan MA, Dagtekin F, Colak C. Incidence and clinical presentation of portal vein thrombosis in cirrhotic patients. *Hepatobiliary Pancreat Dis Int* 2016;15:499-503.
  - 106) Cool J, Rosenblatt R, Kumar S, Lucero C, Fortune B, Crawford C, et al. Portal vein thrombosis prevalence and associated mortality in cirrhosis in a nationally representative inpatient cohort. *J Gastroenterol Hepatol* 2019;34:1088-1092.
  - 107) Fan X, Huang X, Hershman M, Zheng X, Jiang C, Yue B, et al. Portal vein thrombosis prevalence and mortality among alcoholic cirrhosis in a nationwide inpatient cohort. *Eur J Gastroenterol Hepatol* 2019;32:1160-1167.
  - 108) Stine JG, Shah NL, Argo CK, Pelletier SJ, Caldwell SH, Northup PG. Increased risk of portal vein thrombosis in patients with cirrhosis due to nonalcoholic steatohepatitis. *Liver Transpl* 2015;21:1016-1021.
  - 109) Ogren M, Bergqvist D, Bjorck M, Acosta S, Eriksson H, Sternby NH. Portal vein thrombosis: prevalence, patient characteristics and lifetime risk: a population study based on 23,796 consecutive autopsies. *World J Gastroenterol* 2006;12:2115-2119.

- 110) Violi F, Corazza GR, Caldwell SH, Perticone F, Gatta A, Angelico M, et al. Portal vein thrombosis relevance on liver cirrhosis: Italian Venous Thrombotic Events Registry. *Intern Emerg Med* 2016;11:1059-1066.
- 111) Violi F, Corazza G, Caldwell S, Talerico G, Romiti G, Napoleone L, et al. Incidence and recurrence of portal vein thrombosis in cirrhotic patients. *Thromb Haemost* 2019;119:496-499.
- 112) Francoz C, Belghiti J, Vilgrain V, Sommacale D, Paradis V, Condat B, et al. Splanchnic vein thrombosis in candidates for liver transplantation: usefulness of screening and anticoagulation. *Gut* 2005;54:691-697.
- 113) Nery F, Chevret S, Condat B, de Raucourt E, Boudaoud L, Rautou P-E, et al. Causes and consequences of portal vein thrombosis in 1,243 patients with cirrhosis: results of a longitudinal study. *HEPATOLOGY* 2015;61:660-667.
- 114) Noronha Ferreira C, Marinho RT, Cortez-Pinto H, Ferreira P, Dias MS, Vasconcelos M, et al. Incidence, predictive factors and clinical significance of development of portal vein thrombosis in cirrhosis: a prospective study. *Liver Int* 2019;39:1459-1467.
- 115) Nery F, Correia S, Macedo C, Gandara J, Lopes V, Valadares D, et al. Nonselective beta-blockers and the risk of portal vein thrombosis in patients with cirrhosis: results of a prospective longitudinal study. *Aliment Pharmacol Ther* 2019;49:582-588.
- 116) Gaballa D, Bezinover D, Kadry Z, Eyster E, Wang M, Northup PG, et al. Development of a model to predict portal vein thrombosis in liver transplant candidates: the portal vein thrombosis risk index. *Liver Transpl* 2019;25:1747-1755.
- 117) Stine JG, Wang J, Shah PM, Argo CK, Intagliata N, Uflacker A, et al. Decreased portal vein velocity is predictive of the development of portal vein thrombosis: a matched case-control study. *Liver Int* 2018;38:94-101.
- 118) Abdel-Razik A, Mousa N, Elhelaly R, Tawfik A. De-novo portal vein thrombosis in liver cirrhosis: risk factors and correlation with the Model for End-stage Liver Disease scoring system. *Eur J Gastroenterol Hepatol* 2015;27:585-592.
- 119) Zocco MA, Di Stasio E, De Cristofaro R, Novi M, Ainora ME, Ponziani F, et al. Thrombotic risk factors in patients with liver cirrhosis: correlation with MELD scoring system and portal vein thrombosis development. *J Hepatol* 2009;51:682-689.
- 120) Cui SB, Fu Z, Feng YM, Xie XY, Ma XW, Liu TT, et al. The disseminated intravascular coagulation score is a novel predictor for portal vein thrombosis in cirrhotic patients with hepatitis B. *Thromb Res* 2018;161:7-11.
- 121) Maruyama H, Okugawa H, Takahashi M, Yokosuka O. De novo portal vein thrombosis in virus-related cirrhosis: predictive factors and long-term outcomes. *Am J Gastroenterol* 2013;108:568-574.
- 122) Xu X, Guo X, De Stefano V, Silva-Junior G, Goyal H, Bai Z, et al. Nonselective beta-blockers and development of portal vein thrombosis in liver cirrhosis: a systematic review and meta-analysis. *Hepatol Int* 2019;13:468-481.
- 123) Zampino R, Lebaro R, Coppola N, Macera M, Grandone A, Rinaldi L, et al. The use of nonselective beta blockers is a risk factor for portal vein thrombosis in cirrhotic patients. *Saudi J Gastroenterol* 2018;24:25-29.
- 124) Kalambokis GN, Oikonomou A, Christou L, Baltayiannis G. High von Willebrand factor antigen levels and procoagulant imbalance may be involved in both increasing severity of cirrhosis and portal vein thrombosis. *HEPATOLOGY* 2016;64:1383-1385.
- 125) Villa E, Cammà C, Marietta M, Luongo M, Critelli R, Colopi S, et al. Enoxaparin prevents portal vein thrombosis and liver decompensation in patients with advanced cirrhosis. *Gastroenterology* 2012;143:1253-1260.e4.
- 126) Stine JG, Argo CK, Pelletier SJ, Maluf DG, Caldwell SH, Northup PG. Advanced non-alcoholic steatohepatitis cirrhosis: a high-risk population for pre-liver transplant portal vein thrombosis. *World J Hepatol* 2017;9:139-146.
- 127) Ayala R, Grande S, Bustelos R, Ribera C, García-Sesma A, Jimenez C, et al. Obesity is an independent risk factor for pre-transplant portal vein thrombosis in liver recipients. *BMC Gastroenterol* 2012;12:114.
- 128) Hernández-Conde M, Llop E, Fernández-Carrillo C, Perelló C, López-Gómez M, Abad J, et al. Visceral fat is associated with cirrhotic portal vein thrombosis. *Expert Rev Gastroenterol Hepatol* 2019;13:1017-1022.
- 129) Ma SD, Wang J, Bezinover D, Kadry Z, Northup PG, Stine JG. Inherited thrombophilia and portal vein thrombosis in cirrhosis: a systematic review and meta-analysis. *Res Pract Thromb Haemost* 2019;3:658-667.
- 130) Margini C, Berzigotti A. Portal vein thrombosis: the role of imaging in the clinical setting. *Dig Liver Dis* 2017;49:113-120.
- 131) Sandrasegaran K, Tahir B, Nutakki K, Akisik FM, Bodanapally U, Tann M, et al. Usefulness of conventional MRI sequences and diffusion-weighted imaging in differentiating malignant from benign portal vein thrombus in cirrhotic patients. *Am J Roentgenol* 2013;201:1211-1219.
- 132) Tublin ME, Dodd GD III, Baron RL. Benign and malignant portal vein thrombosis: differentiation by CT characteristics. *Am J Roentgenol* 1997;168:719-723.
- 133) Ageno W, Dentali F, Pomero F, Fenoglio L, Squizzato A, Pagani G, et al. Incidence rates and case fatality rates of portal vein thrombosis and Budd-Chiari syndrome. *Thromb Haemost* 2017;117:794-800.
- 134) Darwish Murad S, Plessier A, Hernandez-Guerra M, Fabris F, Eapen CE, Bahr MJ, et al. Etiology, management, and outcome of the Budd-Chiari syndrome. *Ann Intern Med* 2009;151:167-175.
- 135) Kiladjian JJ, Cervantes F, Leebeek FWG, Marzac C, Cassinat B, Chevret S, et al. The impact of JAK2 and MPL mutations on diagnosis and prognosis of splanchnic vein thrombosis: a report on 241 cases. *Blood* 2008;111:4922-4929.
- 136) Berry K, Taylor J, Liou IW, Ioannou GN. Portal vein thrombosis is not associated with increased mortality among patients with cirrhosis. *Clin Gastroenterol Hepatol* 2015;13:585-593.
- 137) John BV, Konjeti R, Aggarwal A, Lopez R, Atreja A, Miller C, et al. Impact of untreated portal vein thrombosis on pre and post liver transplant outcomes in cirrhosis. *Ann Hepatol* 2013;12:952-958.
- 138) Englesbe MJ, Kubus J, Muhammad W, Sonnenday CJ, Welling T, Punch JD, et al. Portal vein thrombosis and survival in patients with cirrhosis. *Liver Transpl* 2010;16:83-90.
- 139) Englesbe MJ, Schaubel DE, Cai S, Guidinger MK, Merion RM. Portal vein thrombosis and liver transplant survival benefit. *Liver Transpl* 2010;16:999-1005.
- 140) Kwong A, Kim WR, Lake JR, Smith JM, Schladt DP, Skeans MA, et al. OPTN/SRTR 2018 annual data report: liver. *Am J Transplant* 2020;20(Suppl. 1):193-299.
- 141) Stine JG, Pelletier SJ, Schmitt TM, Porte RJ, Northup PG. Pre-transplant portal vein thrombosis is an independent risk factor for graft loss due to hepatic artery thrombosis in liver transplant recipients. *HPB (Oxford)* 2016;18:279-286.
- 142) de Franchis R, Baveno VIF. Expanding consensus in portal hypertension: report of the Baveno VI Consensus Workshop: stratifying risk and individualizing care for portal hypertension. *J Hepatol* 2015;63:743-752.
- 143) Guillaume M, Christol C, Plessier A, Corbic M, Péron JM, Sommet A, et al. Bleeding risk of variceal band ligation in extrahepatic portal vein obstruction is not increased by oral anticoagulation. *Eur J Gastroenterol Hepatol* 2018;30:563-568.

- 144) Naymagon L, Tremblay D, Schiano T, Mascarenhas J. The role of anticoagulation in pylephlebitis: a retrospective examination of characteristics and outcomes. *J Thromb Thrombolysis* 2020;49:325-331.
- 145) Hollingshead M, Burke CT, Mauro MA, Weeks SM, Dixon RG, Jaques PF. Transcatheter thrombolytic therapy for acute mesenteric and portal vein thrombosis. *J Vasc Interv Radiol* 2005;16:651-661.
- 146) Liu K, Li WD, Du XL, Li CL, Li XQ. Comparison of systemic thrombolysis versus indirect thrombolysis via the superior mesenteric artery in patients with acute portal vein thrombosis. *Ann Vasc Surg* 2017;39:264-269.
- 147) Smalberg JH, Spaander MVMCW, Jie KS, Pattynama PMT, van Buuren HR, van den Berg B, et al. Risks and benefits of transcatheter thrombolytic therapy in patients with splanchnic venous thrombosis. *Thromb Haemost* 2008;100:1084-1088.
- 148) Cao G, Ko GY, Sung KB, Yoon HK, Gwon DI, Kim JH. Treatment of postoperative main portal vein and superior mesenteric vein thrombosis with balloon angioplasty and/or stent placement. *Acta Radiol* 2013;54:526-532.
- 149) Klinger C, Riecken B, Schmidt A, De Gottardi A, Meier B, Bosch J, et al. Transjugular portal vein recanalization with creation of intrahepatic portosystemic shunt (PVR-TIPS) in patients with chronic non-cirrhotic, non-malignant portal vein thrombosis. *Z Gastroenterol* 2018;56:221-237.
- 150) Rosenqvist K, Eriksson LG, Rorsman F, Sangfelt P, Nyman R. Endovascular treatment of acute and chronic portal vein thrombosis in patients with cirrhotic and non-cirrhotic liver. *Acta Radiol* 2016;57:572-579.
- 151) Salem R, Vouche M, Baker T, Herrero JI, Caicedo JC, Fryer J, et al. Pretransplant portal vein recanalization-transjugular intrahepatic portosystemic shunt in patients with complete obliterative portal vein thrombosis. *Transplantation* 2015;99:2347-2355.
- 152) Thornburg B, Desai K, Hickey R, Hohlastos E, Kulik L, Ganger D, et al. Pretransplantation portal vein recanalization and transjugular intrahepatic portosystemic shunt creation for chronic portal vein thrombosis: final analysis of a 61-patient cohort. *J Vasc Interv Radiol* 2017;28:1714-1721.e2.
- 153) Valentin N, Korrapati P, Constantino J, Young A, Weisberg I. The role of transjugular intrahepatic portosystemic shunt in the management of portal vein thrombosis: a systematic review and meta-analysis. *Eur J Gastro Hepatol* 2018;30:1187-1193.
- 154) Kallini JR, Gabr A, Kulik L, Ganger D, Lewandowski R, Thornburg B, et al. Noncirrhotic complete obliterative portal vein thrombosis: novel management using trans-splenic transjugular intrahepatic portosystemic shunt with portal vein recanalization. *HEPATOLOGY* 2016;63:1387-1390.
- 155) Marot A, Barbosa JV, Duran R, Deltenre P, Denys A. Percutaneous portal vein recanalization using self-expandable nitinol stents in patients with non-cirrhotic non-tumoral portal vein occlusion. *Diagn Interv Imaging* 2019;100:147-156.
- 156) Intagliata NM, Henry ZH, Maitland H, Shah NL, Argo CK, Northup PG, et al. Direct oral anticoagulants in cirrhosis patients pose similar risks of bleeding when compared to traditional anticoagulation. *Dig Dis Sci* 2016;61:1721-1727.
- 157) Intagliata NM, Caldwell SH, Tripodi A. Diagnosis, development, and treatment of portal vein thrombosis in patients with and without cirrhosis. *Gastroenterology* 2019;156:1582-1599.e1.
- 158) Ageno W, Beyer-Westendorf J, Garcia DA, Lazo-Langner A, McBane RD, Paciaroni M. Guidance for the management of venous thrombosis in unusual sites. *J Thromb Thrombolysis* 2016;41:129-143.
- 159) Kearon C, Akl EA, Comerota AJ, Prandoni P, Bounameaux H, Goldhaber SZ, et al. Antithrombotic therapy for VTE disease: antithrombotic therapy and prevention of thrombosis, 9th ed: American College of Chest Physicians evidence-based clinical practice guidelines. *Chest* 2012;141(2 Suppl.):e419S-e496S.
- 160) Amitrano L, Guardascione MA, Menchise A, Martino R, Scaglione M, Giovine S, et al. Safety and efficacy of anticoagulation therapy with low molecular weight heparin for portal vein thrombosis in patients with liver cirrhosis. *J Clin Gastroenterol* 2010;44:448-451.
- 161) Chen H, Liu L, Qi X, He C, Wu F, Fan D, et al. Efficacy and safety of anticoagulation in more advanced portal vein thrombosis in patients with liver cirrhosis. *Eur J Gastroenterol Hepatol* 2016;28:82-89.
- 162) Chung JW, Kim GH, Lee JH, Ok KS, Jang ES, Jeong SH, et al. Safety, efficacy, and response predictors of anticoagulation for the treatment of nonmalignant portal-vein thrombosis in patients with cirrhosis: a propensity score matching analysis. *Clin Mol Hepatol* 2014;20:384-391.
- 163) Cui SB, Shu RH, Yan SP, Wu H, Chen Y, Wang L, et al. Efficacy and safety of anticoagulation therapy with different doses of enoxaparin for portal vein thrombosis in cirrhotic patients with hepatitis B. *Eur J Gastroenterol Hepatol* 2015;27:914-919.
- 164) Delgado MG, Seijo S, Yepes I, Achezar L, Catalina MV, Garcia-Criado A, et al. Efficacy and safety of anticoagulation on patients with cirrhosis and portal vein thrombosis. *Clin Gastroenterol Hepatol* 2012;10:776-783.
- 165) Kwon J, Koh Y, Yu SJ, Yoon JH. Low-molecular-weight heparin treatment for portal vein thrombosis in liver cirrhosis: efficacy and the risk of hemorrhagic complications. *Thromb Res* 2018;163:71-76.
- 166) La Mura V, Braham S, Tosetti G, Branchi F, Bitto N, Moia M, et al. Harmful and beneficial effects of anticoagulants in patients with cirrhosis and portal vein thrombosis. *Clin Gastroenterol Hepatol* 2018;16:1146-1152.e4.
- 167) Rodriguez-Castro KI, Vitale A, Fadin M, Shalaby S, Zerbini P, Sartori MT, et al. A prediction model for successful anticoagulation in cirrhotic portal vein thrombosis. *Eur J Gastroenterol Hepatol* 2019;31:34-42.
- 168) Senzolo MM, Sartori T, Rossetto V, Burra P, Cillo U, Boccagni P, et al. Prospective evaluation of anticoagulation and transjugular intrahepatic portosystemic shunt for the management of portal vein thrombosis in cirrhosis. *Liver Int* 2012;32:919-927.
- 169) Werner KT, Sando S, Carey EJ, Vargas HE, Byrne TJ, Douglas DD, et al. Portal vein thrombosis in patients with end stage liver disease awaiting liver transplantation: outcome of anticoagulation. *Dig Dis Sci* 2013;58:1776-1780.
- 170) Loffredo L, Pastori D, Farcomeni A, Violi F. Effects of anticoagulants in patients with cirrhosis and portal vein thrombosis: a systematic review and meta-analysis. *Gastroenterology* 2017;153:480-487.e1.
- 171) Qi X, Guo X, Yoshida EM, Mendez-Sanchez N, De Stefano V, Tacke F, et al. Transient portal vein thrombosis in liver cirrhosis. *BMC Med* 2018;16:83.
- 172) Northup P, Reutemann B. Management of coagulation and anticoagulation in liver transplantation candidates. *Liver Transpl* 2018;24:1119-1132.
- 173) Cerini F, Gonzalez JM, Torres F, Puente A, Casas M, Vinaixa C, et al. Impact of anticoagulation on upper-gastrointestinal bleeding in cirrhosis. A retrospective multicenter study. *HEPATOLOGY* 2015;62:575-583.
- 174) Potte W, Adelmeijer J, Lisman T. Decreased in vitro anticoagulant potency of Rivaroxaban and Apixaban in plasma from patients with cirrhosis. *HEPATOLOGY* 2015;61:1435-1436.
- 175) Potte W, Arshad F, Adelmeijer J, Blokzijl H, van den Berg AP, Meijers JC, et al. Differential in vitro inhibition of thrombin generation by anticoagulant drugs in plasma from patients with cirrhosis. *PLoS One* 2014;9:e88390.



- 176) Bos S, Schreuder T, Blokzijl H, Adelmeijer J, Lismann T, Kamphuisen PW. Anticoagulant activity of edoxaban in patients with cirrhosis. *Blood* 2020;136:1561-1564.
- 177) Mort JF, Davis JP, Giselle M, Stotts MJ, Intagliata NM, Northup PG. Rates of bleeding and discontinuation of direct oral anticoagulants in patients with decompensated cirrhosis. *Clin Gastroenterol Hepatol* 2020 Aug 8. <https://doi.org/10.1016/j.cgh.2020.08.007>. [Epub ahead of print]
- 178) De Gottardi A, Trebicka J, Klinger C, Plessier A, Seijo S, Terziroli B, et al. Antithrombotic treatment with direct-acting oral anticoagulants in patients with splanchnic vein thrombosis and cirrhosis. *Liver Int* 2017;37:694-699.
- 179) Hum J, Shatzel JJ, Jou JH, Deloughery TG. The efficacy and safety of direct oral anticoagulants vs traditional anticoagulants in cirrhosis. *Eur J Haematol* 2017;98:393-397.
- 180) Intagliata NM, Maitland H, Northup PG, Caldwell SH. Treating thrombosis in cirrhosis patients with new oral agents: ready or not? *HEPATOLOGY* 2015;61:738-739.
- 181) Serper M, Weinberg EM, Cohen JB, Reese PP, Taddei TH, Kaplan DE. Mortality and hepatic decompensation in patients with cirrhosis and atrial fibrillation treated with anticoagulation. *HEPATOLOGY* 2020 Apr 8. <https://doi.org/10.1002/hep.31264>. [Epub ahead of print]
- 182) Lee HF, Chan YH, Chang SH, Tu HT, Chen SW, Yeh YH, et al. Effectiveness and safety of non-Vitamin K antagonist oral anticoagulant and warfarin in cirrhotic patients with nonvalvular atrial fibrillation. *J Am Heart Assoc* 2019;8:e011112.
- 183) Lee SR, Lee HJ, Choi EK, Han KD, Jung JH, Cha MJ, et al. Direct oral anticoagulants in patients with atrial fibrillation and liver disease. *J Am Coll Cardiol* 2019;73:3295-3308.
- 184) Intagliata NM, Maitland H, Pellitier S, Caldwell SH. Reversal of direct oral anticoagulants for liver transplantation in cirrhosis: a step forward. *Liver Transpl* 2017;23:396-397.
- 185) Hanafy AS, Abd-Elsalam S, Dawoud MM. Randomized controlled trial of rivaroxaban versus warfarin in the management of acute non-neoplastic portal vein thrombosis. *Vascul Pharmacol* 2019;113:86-91.
- 186) Nagaoki Y, Aikata H, Daijyo K, Teraoka Y, Shinohara F, Nakamura Y, et al. Efficacy and safety of edoxaban for treatment of portal vein thrombosis following danaparoid sodium in patients with liver cirrhosis. *Hepatol Res* 2018;48:51-58.
- 187) Condat B, Pessione F, Hillaire S, Denninger MH, Guillin MC, Poliquin M, et al. Current outcome of portal vein thrombosis in adults: risk and benefit of anticoagulant therapy. *Gastroenterology* 2001;120:490-497.
- 188) Orr DW, Harrison PM, Devlin J, Karani JB, Kane PA, Heaton ND, et al. Chronic mesenteric venous thrombosis: evaluation and determinants of survival during long-term follow-up. *Clin Gastroenterol Hepatol* 2007;5:80-86.
- 189) Spaander MC, Hoekstra J, Hansen BE, Van Buuren HR, Leebeek FW, Janssen HL. Anticoagulant therapy in patients with non-cirrhotic portal vein thrombosis: effect on new thrombotic events and gastrointestinal bleeding. *J Thromb Haemost* 2013;11:452-459.
- 190) Noronha Ferreira C, Seijo S, Plessier A, Silva-Junior G, Turon F, Rautou PE, et al. Natural history and management of esophagogastric varices in chronic noncirrhotic, nontumoral portal vein thrombosis. *HEPATOLOGY* 2016;63:1640-1650.
- 191) Ageno W, Riva N, Schulman S, Beyer-Westendorf J, Bang SM, Senzolo M, et al. Long-term clinical outcomes of splanchnic vein thrombosis: results of an international registry. *JAMA Intern Med* 2015;175:1474-1480.
- 192) Riva N, Ageno W, Poli D, Testa S, Rupoli S, Santoro R, et al. Safety of vitamin K antagonist treatment for splanchnic vein thrombosis: a multicenter cohort study. *J Thromb Haemost* 2015;13:1019-1027.
- 193) Agnelli G, Buller HR, Cohen A, Curto M, Gallus AS, Johnson M, et al. Oral apixaban for the treatment of acute venous thromboembolism. *N Engl J Med* 2013;369:799-808.
- 194) Janczak DT, Mimier MK, McBane RD, Kamath PS, Simmons BS, Bott-Kitslaar DM, et al. Rivaroxaban and apixaban for initial treatment of acute venous thromboembolism of atypical location. *Mayo Clin Proc* 2018;93:40-47.
- 195) Nery F, Valadares D, Morais S, Gomes MT, De Gottardi A. Efficacy and safety of direct-acting oral anticoagulants use in acute portal vein thrombosis unrelated to cirrhosis. *Gastroenterology Res* 2017;10:141-143.
- 196) Naymagon L, Tremblay D, Zubizarreta N, Moshier E, Troy K, Schiano T, et al. The efficacy and safety of direct oral anticoagulants in noncirrhotic portal vein thrombosis. *Blood Adv* 2020;4:655-666.
- 197) Li A, Garcia DA, Lyman GH, Carrier M. Direct oral anticoagulant (DOAC) versus low-molecular-weight heparin (LMWH) for treatment of cancer associated thrombosis (CAT): a systematic review and meta-analysis. *Thromb Res* 2019;173:158-163.
- 198) Ollivier-Hourmand I, Allaire M, Goutte N, Morello R, Chagneau-Derode C, Gorla O, et al. The epidemiology of Budd-Chiari syndrome in France. *Dig Liver Dis* 2018;50:931-937.
- 199) Qi X, Wu F, Ren W, He C, Yin Z, Niu J, et al. Thrombotic risk factors in Chinese Budd-Chiari syndrome patients. An observational study with a systematic review of the literature. *Thromb Haemost* 2013;109:878-884.
- 200) Fan J, Wang Q, Luo B, Chen H, Wang Z, Niu J, et al. Prevalence of prothrombotic factors in patients with Budd-Chiari syndrome or non-cirrhotic nonmalignant portal vein thrombosis: a hospital-based observational study. *J Gastroenterol Hepatol* 2020;35:1215-1222.
- 201) Seijo S, Plessier A, Hoekstra J, Dell'Era A, Mandair D, Rifai K, et al. Good long-term outcome of Budd-Chiari syndrome with a step-wise management. *HEPATOLOGY* 2013;57:1962-1968.
- 202) Hadengue A, Poliquin M, Vilgrain V, Belghiti J, Degott C, Erlinger S, et al. The changing scene of hepatic vein thrombosis: recognition of asymptomatic cases. *Gastroenterology* 1994;106:1042-1047.
- 203) Vilgrain V, Lewin M, Vons C, Denys A, Valla D, Flejou JF, et al. Hepatic nodules in Budd-Chiari syndrome: imaging features. *Radiology* 1999;210:443-450.
- 204) Sempoux C, Paradis V, Komuta M, Wee A, Calderaro J, Balabaud C, et al. Hepatocellular nodules expressing markers of hepatocellular adenomas in Budd-Chiari syndrome and other rare hepatic vascular disorders. *J Hepatol* 2015;63:1173-1180.
- 205) Moucari R, Rautou PE, Cazals-Hatem D, Gera A, Bureau C, Consigny Y, et al. Hepatocellular carcinoma in Budd-Chiari syndrome: characteristics and risk factors. *Gut* 2008;57:828-835.
- 206) Ren W, Qi X, Yang Z, Han G, Fan D. Prevalence and risk factors of hepatocellular carcinoma in Budd-Chiari syndrome: a systematic review. *Eur J Gastroenterol Hepatol* 2013;25:830-841.
- 207) Van Wettere M, Purcell Y, Bruno O, Payancé A, Plessier A, Rautou PE, et al. Low specificity of washout to diagnose hepatocellular carcinoma in nodules showing arterial hyperenhancement in patients with Budd-Chiari syndrome. *J Hepatol* 2019;70:1123-1132.
- 208) Chernyak V, Santillan CS, Papadatos D, Sirlin CB. LI-RADS® algorithm: CT and MRI. *Abdom Radiol* 2018;43:111-126.
- 209) Bargallo X, Gilibert R, Nicolau C, Garcia-Pagan JC, Ayuso JR, Bru C. Sonography of Budd-Chiari syndrome. *Am J Roentgenol* 2006;187:W33-W41.
- 210) Plessier A, Sibert A, Consigny Y, Hakime A, Zappa M, Denninger MH, et al. Aiming at minimal invasiveness as a therapeutic strategy for Budd-Chiari syndrome. *HEPATOLOGY* 2006;44:1308-1316.



- 211) Sharma S, Texeira A, Texeira P, Elias E, Wilde J, Olliff SP. Pharmacological thrombolysis in Budd Chiari syndrome: a single centre experience and review of the literature. *J Hepatol* 2004;40:172-180.
- 212) Han G, Qi X, Zhang W, He C, Yin Z, Wang J, et al. Percutaneous recanalization for Budd-Chiari syndrome: an 11-year retrospective study on patency and survival in 177 Chinese patients from a single center. *Radiology* 2013;266:657-667.
- 213) Valla D, Hadengue A, el Younsi M, Azar N, Zeitoun G, Boudet M, et al. Hepatic venous outflow block caused by short-length hepatic vein stenoses. *HEPATOLOGY* 1997;25:814-819.
- 214) Cheng DL, Xu H, Li CL, Lv WF, Li CT, Mukhiya G, et al. Interventional treatment strategy for primary Budd-Chiari syndrome with both inferior vena cava and hepatic vein involvement: patients from two centers in China. *Cardiovasc Intervent Radiol* 2019;42:1311-1321.
- 215) Wang Q, Li K, He C, Yuan X, Luo B, Qi X, et al. Angioplasty with versus without routine stent placement for Budd-Chiari syndrome: a randomised controlled trial. *Lancet Gastroenterol Hepatol* 2019;4:686-697.
- 216) Ferrusquia-Acosta J, Hernandez-Gea V, Turon F, Garcia-Pagan JC. Budd-Chiari syndrome with short-length stenosis: still room for the angioplasty and wait-and-see strategy. *Lancet Gastroenterol Hepatol* 2019;4:823.
- 217) Bi Y, Chen H, Ding P, Ren J, Han X. Comparison of retrievable stents and permanent stents for Budd-Chiari syndrome due to obstructive inferior vena cava. *J Gastroenterol Hepatol* 2018;33:2015-2021.
- 218) Shaked A, Goldstein RM, Klintmalm GB, Drazen K, Husberg B, Busuttil RW. Portosystemic shunt versus orthotopic liver transplantation for the Budd-Chiari syndrome. *Surg Gynecol Obstet* 1992;174:453-459.
- 219) Klein AS, Molmenti EP. Surgical treatment of Budd-Chiari syndrome. *Liver Transpl* 2003;9:891-896.
- 220) Chen H, Zhang F, Ye Y, Cheng Y, Chen Y. Long-term follow-up study and comparison of meso-atrial shunts and meso-cavo-atrial shunts for treatment of combined Budd-Chiari syndrome. *J Surg Res* 2011;168:162-166.
- 221) Garcia-Pagan JC, Heydtmann M, Raffa S, Plessier A, Murad S, Fabris F, et al. TIPS for Budd-Chiari syndrome: long-term results and prognostic factors in 124 patients. *Gastroenterology* 2008;135:808-815.
- 222) Mancuso A. In favour of early intervention for Budd-Chiari syndrome: another brick in the wall. *Eur J Gastroenterol Hepatol* 2016;28:850-851.
- 223) Wang HW, Shi HN, Cheng J, Xie F, Luo YK, Tang J. Real-time shear wave elastography (SWE) assessment of short- and long-term treatment outcome in Budd-Chiari syndrome: a pilot study. *PLoS One* 2018;13:e0197550.
- 224) Xu P, Lyu L, Ge H, Sami MU, Liu P, Hu C, et al. Segmental liver stiffness evaluated with magnetic resonance elastography is responsive to endovascular intervention in patients with Budd-Chiari syndrome. *Korean J Radiol* 2019;20:773-780.
- 225) Mentha G, Giostra E, Majno PE, Bechstein WO, Neuhaus P, O'Grady J, et al. Liver transplantation for Budd-Chiari syndrome: a European study on 248 patients from 51 centres. *J Hepatol* 2006;44:520-528.
- 226) Karaca C, Yilmaz C, Ferecova R, Iakobadze Z, Kilic K, Caglayan L, et al. Living-donor liver transplantation for Budd-Chiari syndrome: case series. *Transplant Proc* 2017;49:1841-1847.
- 227) Chinnakotla S, Klintmalm GB, Kim P, Tomiyama K, Klintmalm E, Davis GL, et al. Long-term follow-up of liver transplantation for Budd-Chiari syndrome with antithrombotic therapy based on the etiology. *Transplantation* 2011;92:341-345.
- 228) Valla DC, Cazals-Hatem D. Sinusoidal obstruction syndrome. *Clin Res Hepatol Gastroenterol* 2016;40:378-385.
- 229) Tandon BN, Tandon HD, Tandon RK, Narndranathan M, Joshi YK. An epidemic of veno-occlusive disease of liver in central India. *Lancet* 1976;2:271-272.
- 230) Tandon RK, Tandon BN, Tandon HD, Bhatia ML, Bhargava S, Lal P, et al. Study of an epidemic of venoocclusive disease in India. *Gut* 1976;17:849-855.
- 231) Jones RJ, Lee KSK, Beschoner WE, Vogel VG, Grochow LB, Braine HG, et al. Venocclusive disease of the liver following bone marrow transplantation. *Transplantation* 1987;44:778-783.
- 232) Mohty M, Malard F, Abecassis M, Aerts E, Alaskar AS, Aljurf M, et al. Revised diagnosis and severity criteria for sinusoidal obstruction syndrome/veno-occlusive disease in adult patients: a new classification from the European Society for Blood and Marrow Transplantation. *Bone Marrow Transplant* 2016;51:906-912.
- 233) McDonald GB, Sharma P, Matthews DE, Shulman HM, Thomas ED. Venocclusive disease of the liver after bone marrow transplantation: diagnosis, incidence, and predisposing factors. *HEPATOLOGY* 1984;4:116-122.
- 234) Shulman HM, Gooley T, Dudley MD, Kofler T, Feldman R, Dwyer D, et al. Utility of transvenous liver biopsies and wedged hepatic venous pressure measurements in sixty marrow transplant recipients. *Transplantation* 1995;59:1015-1022.
- 235) Carreras E, Bertz H, Arcese W, Vernant JP, Tomas JF, Hagglund H, et al. Incidence and outcome of hepatic veno-occlusive disease after blood or marrow transplantation: a prospective cohort study of the European Group for Blood and Marrow Transplantation. European Group for Blood and Marrow Transplantation Chronic Leukemia Working Party. *Blood* 1998;92:3599-3604.
- 236) Carreras E, Díaz-Beyá M, Rosiñol L, Martínez C, Fernández-Avilés F, Rovira M. The incidence of veno-occlusive disease following allogeneic hematopoietic stem cell transplantation has diminished and the outcome improved over the last decade. *Biol Blood Marrow Transplant* 2011;17:1713-1720.
- 237) Bodge MN, Culos KA, Haider SN, Thompson MS, Savani BN. Preparative regimen dosing for hematopoietic stem cell transplantation in patients with chronic hepatic impairment: analysis of the literature and recommendations. *Biol Blood Marrow Transplant* 2014;20:622-629.
- 238) Auberger J, Graziadei I, Clausen J, Vogel W, Nachbaur D. Non-invasive transient elastography for the prediction of liver toxicity following hematopoietic SCT. *Bone Marrow Transplant* 2013;48:159-160.
- 239) Karlas T, Weber J, Nehring C, Kronenberger R, Tenckhoff H, Mössner J, et al. Value of liver elastography and abdominal ultrasound for detection of complications of allogeneic hemopoietic SCT. *Bone Marrow Transplant* 2014;49:806-811.
- 240) Colecchia A, Ravaioli F, Sessa M, Alemanni VL, Dajti E, Marasco G, et al. Liver stiffness measurement allows early diagnosis of veno-occlusive disease/sinusoidal obstruction syndrome in adult patients who undergo hematopoietic stem cell transplantation: results from a monocentric prospective study. *Biol Blood Marrow Transplant* 2019;25:995-1003.
- 241) Essell JH, Schroeder MT, Harman GS, Halvorson R, Lew V, Callander N, et al. Ursodiol prophylaxis against hepatic complications of allogeneic bone marrow transplantation: a randomized, double-blind, placebo-controlled trial. *Ann Int Med* 1998;128:975-981.
- 242) Ohashi K, Tanabe J, Watanabe R, Tanaka T, Sakamaki H, Maruta A, et al. The Japanese multicenter open randomized trial of ursodeoxycholic acid prophylaxis for hepatic veno-occlusive disease after stem cell transplantation. *Am J Hematol* 2000;64:32-38.
- 243) Park SH, Lee MH, Lee H, Kim HS, Kim K, Kim WS, et al. A randomized trial of heparin plus ursodiol vs heparin alone to prevent hepatic veno-occlusive disease after hematopoietic stem cell transplantation. *Bone Marrow Transplant* 2002;29:137-143.

- 244) Ruutu T, Eriksson B, Remes K, Juvonen E, Volin L, Remberger M, et al. Ursodeoxycholic acid for the prevention of hepatic complications in allogeneic stem cell transplantation. *Blood* 2002;100:1977-1983.
- 245) Tay J, Tinmouth A, Fergusson D, Huebsch L, Allan DS. Systematic review of controlled clinical trials on the use of ursodeoxycholic acid for the prevention of hepatic veno-occlusive disease in hematopoietic stem cell transplantation. *Biol Blood Marrow Transplant* 2007;13:206-217.
- 246) Dignan FL, Wynn RF, Hadzic N, Karani J, Quaglia A, Pagliuca A, et al. BCSH/BSBMT guideline: diagnosis and management of veno-occlusive disease (sinusoidal obstruction syndrome) following haematopoietic stem cell transplantation. *Br J Haematol* 2013;163:444-457.
- 247) Mohty M, Malard F, Abecasis M, Aerts E, Alaskar AS, Aljurf M, et al. Prophylactic, preemptive, and curative treatment for sinusoidal obstruction syndrome/veno-occlusive disease in adult patients: a position statement from an international expert group. *Bone Marrow Transplant* 2020;55:485-495.
- 248) Corbacioglu S, Cesaro S, Faraci M, Valteau-Couanet D, Gruhn B, Rovelli A, et al. Defibrotide for prophylaxis of hepatic veno-occlusive disease in paediatric haematopoietic stem-cell transplantation: an open-label, phase 3, randomised controlled trial. *Lancet* 2012;379:1301-1309.
- 249) Fried MW, Connaghan DG, Sharma S, Martin LG, Devine S, Holland K, et al. Transjugular intrahepatic portosystemic shunt for the management of severe venoocclusive disease following bone marrow transplantation. *HEPATOLOGY* 1996;24:588-591.
- 250) Letteboer TG, Mager JJ, Snijder RJ, Koeleman BP, Lindhout D, Ploos van Amstel JK, et al. Genotype-phenotype relationship in hereditary haemorrhagic telangiectasia. *J Med Genet* 2006;43:371-377.
- 251) Buscarini E, Leandro G, Conte D, Danesino C, Daina E, Manfredi G, et al. Natural history and outcome of hepatic vascular malformations in a large cohort of patients with hereditary hemorrhagic telangiectasia. *Dig Dis Sci* 2011;56:2166-2178.
- 252) Khalid SK, Garcia-Tsao G. Hepatic vascular malformations in hereditary hemorrhagic telangiectasia. *Semin Liver Dis* 2008;28:247-258.
- 253) Garcia-Tsao G, Korzenik JR, Young L, Henderson KJ, Jain D, Byrd B, et al. Liver disease in patients with hereditary hemorrhagic telangiectasia. *N Engl J Med* 2000;343:931-936.
- 254) Buscarini E, Danesino C, Plauchu H, de Fazio C, Olivieri C, Brambilla G, et al. High prevalence of hepatic focal nodular hyperplasia in subjects with hereditary hemorrhagic telangiectasia. *Ultrasound Med Biol* 2004;30:1089-1097.
- 255) Faughnan ME, Mager JJ, Hetts SW, Palda VA, Lang-Robertson K, Buscarini E, et al. Second international guidelines for the diagnosis and management of hereditary hemorrhagic telangiectasia. *Ann Intern Med* 2020 Sep 8. <https://doi.org/10.7326/M20-1443>. [Epub ahead of print]
- 256) Albitar HAH, Almodallal Y, Gallo De Moraes A, O'Brien E, Choby GW, Pruthi RK, et al. Intravenous bevacizumab in hereditary hemorrhagic telangiectasia-related bleeding and high-output cardiac failure: significant inter-individual variability in the need for maintenance therapy. *Mayo Clin Proc* 2020;95:1604-1612.
- 257) Al-Samkari H, Kasthuri RS, Parambil JG, Albitar HA, Almodallal YA, Vazquez C, et al. An international, multicenter study of intravenous bevacizumab for bleeding in hereditary hemorrhagic telangiectasia: the InHIBIT-bleed study. *Haematologica* 2020 Jul 16. <https://doi.org/10.3324/haematol.2020.261859>. [Epub ahead of print]
- 258) Dupuis-Girod S, Ginon I, Saurin JC, Marion D, Guillot E, Decullier E, et al. Bevacizumab in patients with hereditary hemorrhagic telangiectasia and severe hepatic vascular malformations and high cardiac output. *JAMA* 2012;307:948-955.
- 259) Vlachou PA, Colak E, Koculym A, Kirpalani A, Kim TK, Hirschfield GM, et al. Improvement of ischemic cholangiopathy in three patients with hereditary hemorrhagic telangiectasia following treatment with bevacizumab. *J Hepatol* 2013;59:186-189.
- 260) Buscarini E, Manfredi G, Zambelli A. Bevacizumab to treat complicated liver vascular malformations in hereditary hemorrhagic telangiectasia: a word of caution. *Liver Transpl* 2008;14:1685-1686; author reply, 1687-1688.
- 261) Lerut J, Orlando G, Adam R, Sabbà C, Pfitzmann R, Klempnauer J, et al. Liver transplantation for hereditary hemorrhagic telangiectasia: report of the European liver transplant registry. *Ann Surg* 2006;244:854-862; discussion, 862-854.
- 262) Iyer VN, Saberi B, Heimbach JK, Larson JJ, Raghavaiah S, Ditah I, et al. Liver transplantation trends and outcomes for hereditary hemorrhagic telangiectasia in the United States. *Transplantation* 2019;103:1418-1424.
- 263) Dumortier J, Dupuis-Girod S, Valette PJ, Valent A, Guillaud O, Saurin JC, et al. Recurrence of hereditary hemorrhagic telangiectasia after liver transplantation: clinical implications and physiological insights. *HEPATOLOGY* 2019;69:2232-2240.
- 264) Hernández-Gea V, Baiges A, Turon F, García-Pagán JC. Idiopathic portal hypertension. *HEPATOLOGY* 2018;68:2413-2423.
- 265) Schouten JNL, Garcia-Pagan JC, Valla DC, Janssen HLA. Idiopathic noncirrhotic portal hypertension. *HEPATOLOGY* 2011;54:1071-1081.
- 266) Guido M, Alves VAF, Balabaud C, Bathal PS, Bioulac-Sage P, Colombi R, et al. Histology of portal vascular changes associated with idiopathic non-cirrhotic portal hypertension: nomenclature and definition. *Histopathology* 2019;74:219-226.
- 267) Zuo C, Chumbalkar V, Ells PF, Bonville DJ, Lee H. Prevalence of histological features of idiopathic noncirrhotic portal hypertension in general population: a retrospective study of incidental liver biopsies. *Hepatol Int* 2017;11:452-460.
- 268) Guido M, Sarcognato S, Sonzogni A, Lucà MG, Senzolo M, Fagioli S, et al. Obliterative portal venopathy without portal hypertension: an underestimated condition. *Liver Int* 2016;36:454-460.
- 269) De Gottardi A, Rautou PE, Schouten J, Rubbia-Brandt L, Leebeck F, Trebicka J, et al. Porto-sinusoidal vascular disease: proposal and description of a novel entity. *Lancet Gastroenterol Hepatol* 2019;4:399-411.
- 270) Sharma P, Agarwal R, Dhawan S, Bansal N, Singla V, Kumar A, et al. Transient elastography (Fibroscan) in patients with non-cirrhotic portal fibrosis. *J Clin Exp Hepatol* 2017;7:230-234.
- 271) Vuppalanchi R, Mathur K, Pyko M, Samala N, Chalasani N. Liver stiffness measurements in patients with noncirrhotic portal hypertension—the devil is in the details. *HEPATOLOGY* 2018;68:2438-2440.
- 272) Siramolpiwat S, Seijo S, Miquel R, Berzigotti A, Garcia-Criado A, Darnell A, et al. Idiopathic portal hypertension: natural history and long-term outcome. *HEPATOLOGY* 2014;59:2276-2285.
- 273) Schouten JNL, Van der Ende ME, Koëter T, Rossing HHM, Komuta M, Verheij J, et al. Risk factors and outcome of HIV-associated idiopathic noncirrhotic portal hypertension. *Aliment Pharmacol Ther* 2012;36:875-885.
- 274) Cazals-Hatem D, Hillaire S, Rudler M, Plessier A, Paradis V, Condat B, et al. Obliterative portal venopathy: portal hypertension is not always present at diagnosis. *J Hepatol* 2011;54:455-461.
- 275) Hillaire S, Bonte E, Denninger MH, Casadevall N, Cadranel JF, Lebre C, et al. Idiopathic non-cirrhotic intrahepatic portal hypertension in the West: a re-evaluation in 28 patients. *Gut* 2002;51:275-280.
- 276) Gioia S, Nardelli S, Pasquale C, Pentassuglio I, Nicoletti V, Aprile F, et al. Natural history of patients with non cirrhotic

- portal hypertension: comparison with patients with compensated cirrhosis. *Dig Liver Dis* 2018;50:839-844.
- 277) Glatard AS, Hillaire S, d'Assignies G, Cazals-Hatem D, Plessier A, Valla DC, et al. Obliterative portal venopathy: findings at CT imaging. *Radiology* 2012;263:741-750.
  - 278) Bissonnette J, Garcia-Pagán JC, Albillos A, Turon F, Ferreira C, Tellez L, et al. Role of the transjugular intrahepatic portosystemic shunt in the management of severe complications of portal hypertension in idiopathic noncirrhotic portal hypertension. *HEPATOLOGY* 2016;64:224-231.
  - 279) Shanley CJ, Shah NL, Messina LM. Common splanchnic artery aneurysms: splenic, hepatic, and celiac. *Ann Vasc Surg* 1996;10:315-322.
  - 280) Pasha SF, Gloviczki P, Stanson AW, Kamath PS. Splanchnic artery aneurysms. *Mayo Clin Proc* 2007;82:472-479.
  - 281) Abbas MA, Fowl RJ, Stone WM, Panneton JM, Oldenburg WA, Bower TC, et al. Hepatic artery aneurysm: factors that predict complications. *J Vasc Surg* 2003;38:41-45.
  - 282) Lumsden AB, Mattar SG, Allen RC, Bacha EA. Hepatic artery aneurysms: the management of 22 patients. *J Surg Res* 1996;60:345-350.
  - 283) Sessa C, Tinelli G, Porcu P, Aubert A, Thony F, Magne JL. Treatment of visceral artery aneurysms: description of a retrospective series of 42 aneurysms in 34 patients. *Ann Vasc Surg* 2004;18:695-703.
  - 284) Erben Y, De Martino RR, Bjarnason H, Duncan AA, Kalra M, Oderich GS, et al. Operative management of hepatic artery aneurysms. *J Vasc Surg* 2015;62:610-615.
  - 285) Melissano G, Mascia D, Atique Gabriel S, Bertoglio L, Venturini M, Del Maschio A, et al. Hepatic artery aneurysms: open and endovascular repair. *J Cardiovasc Surg (Torino)* 2018;59:95-100.
  - 286) Horejsova M, Bozovska J, Kocandrl V. Aneurysm of the common hepatic artery diagnosed by ultrasonography. *Hepatogastroenterology* 1990;37(Suppl. 2):74-76.
  - 287) Kibbler CC, Cohen DL, Cruickshank JK, Kushwaha SS, Morgan MY, Dick RD. Use of CAT scanning in the diagnosis and management of hepatic artery aneurysm. *Gut* 1985;26:752-756.
  - 288) Berceli SA. Hepatic and splenic artery aneurysms. *Semin Vasc Surg* 2005;18:196-201.
  - 289) Tessier DJ, Stone WM, Fowl RJ, Abbas MA, Andrews JC, Bower TC, et al. Clinical features and management of splenic artery pseudoaneurysm: case series and cumulative review of literature. *J Vasc Surg* 2003;38:969-974.
  - 290) Abbas MA, Stone WM, Fowl RJ, Gloviczki P, Oldenburg WA, Pairolero PC, et al. Splenic artery aneurysms: two decades experience at Mayo clinic. *Ann Vasc Surg* 2002;16:442-449.
  - 291) Sadat U, Dar O, Walsh S, Varty K. Splenic artery aneurysms in pregnancy—a systematic review. *Int J Surg* 2008;6:261-265.
  - 292) Trastek VF, Pairolero PC, Joyce JW, Hollier LH, Bernatz PE. Splenic artery aneurysms. *Surgery* 1982;91:694-699.
  - 293) Hogendoorn W, Lavidia A, Hunink MG, Moll FL, Geroulakos G, Muhs BE, et al. Open repair, endovascular repair, and conservative management of true splenic artery aneurysms. *J Vasc Surg* 2014;60:1667-1676.e1.
  - 294) Therakathu J, Panwala HK, Bhargava S, Eapen A, Keshava SN, David D. Contrast-enhanced computed tomography imaging of splenic artery aneurysms and pseudoaneurysms: a single-center experience. *J Clin Imaging Sci* 2018;8:37.
  - 295) Naganuma M, Matsui H, Koizumi J, Fushimi K, Yasunaga H. Short-term outcomes following elective transcatheter arterial embolization for splenic artery aneurysms: data from a nationwide administrative database. *Acta Radiol Open* 2015;4:2047981615574354.
  - 296) Sellier J, Karam C, Beauchet A, Dallongeville A, Binsse S, Blivet S, et al. Higher prevalence of splenic artery aneurysms in hereditary hemorrhagic telangiectasia: vascular implications and risk factors. *PLoS One* 2020;15:e0226681.
  - 297) Gaglio PJ, Regenstein F, Slakey D, Cheng S, Takiff H, Rinker R, et al. Alpha-1 antitrypsin deficiency and splenic artery aneurysm rupture: an association? *Am J Gastroenterol* 2000;95:1531-1534.
  - 298) Al-Habbal Y, Christophi C, Muralidharan V. Aneurysms of the splenic artery—a review. *Surgeon* 2010;8:223-231.
  - 299) Carr SC, Mahvi DM, Hoch JR, Archer CW, Turnipseed WD. Visceral artery aneurysm rupture. *J Vasc Surg* 2001;33:806-811.
  - 300) Mattar SG, Lumsden AB. The management of splenic artery aneurysms: experience with 23 cases. *Am J Surg* 1995;169:580-584.
  - 301) Pescarus R, Montreuil B, Bendavid Y. Giant splenic artery aneurysms: case report and review of the literature. *J Vasc Surg* 2005;42:344-347.
  - 302) Hamid HKS, Suliman AEA, Piffaretti G, Spiliopoulos S, Tetreau R, Tozzi M, et al. A systematic review on clinical features and management of true giant splenic artery aneurysms. *J Vasc Surg* 2020;71:1036-1045.e1.
  - 303) Nanez L, Knowles M, Modrall JG, Valentine RJ. Ruptured splenic artery aneurysms are exceedingly rare in pregnant women. *J Vasc Surg* 2014;60:1520-1523.
  - 304) Heestand G, Sher L, Lightfoote J, Palmer S, Mateo R, Singh G, et al. Characteristics and management of splenic artery aneurysm in liver transplant candidates and recipients. *Am Surg* 2003;69:933-940.
  - 305) Moon DB, Lee SG, Hwang S, Kim KH, Ahn CS, Ha TY, et al. Characteristics and management of splenic artery aneurysms in adult living donor liver transplant recipients. *Liver Transpl* 2009;15:1535-1541.
  - 306) Gastaca M, Ventoso A, Valdivieso A, de Urbina JO. Management of splenic artery aneurysms in liver transplant recipients. *Liver Transpl* 2010;16:921-922.
  - 307) Kobori L, van der Kolk MJ, de Jong KP, Peeters PM, Klompmaker IJ, Kok T, et al. Splenic artery aneurysms in liver transplant patients. *Liver Transplant Group. J Hepatol* 1997;27:890-893.
  - 308) Kaya M, Baran S, Guya C, Kaplan MA. Prevalence and predictive factors for development of splenic artery aneurysms in cirrhosis. *Indian J Gastroenterol* 2016;35:201-206.
  - 309) Sticco A, Aggarwal A, Shapiro M, Pratt A, Rissuci D, D'Ayala M. A comparison of open and endovascular treatment strategies for the management of splenic artery aneurysms. *Vascular* 2016;24:487-491.
  - 310) Superina R, Bambini DA, Lokar J, Rigsby C, Whittington PF. Correction of extrahepatic portal vein thrombosis by the mesenteric to left portal vein bypass. *Ann Surg* 2006;243:515-521.
  - 311) de Ville de Goyet J, Clapuyt P, Otte JB. Extrahilar mesenterico-left portal shunt to relieve extrahepatic portal hypertension after partial liver transplant. *Transplantation* 1992;53:231-232.
  - 312) Superina R, Shneider B, Emre S, Sarin S, De Ville de Goyet J. Surgical guidelines for the management of extra-hepatic portal vein obstruction. *Pediatr Transplant* 2006;10:908-913.
  - 313) Mack CL, Superina RA, Whittington PF. Surgical restoration of portal flow corrects procoagulant and anticoagulant deficiencies associated with extrahepatic portal vein thrombosis. *J Pediatr* 2003;142:197-199.
  - 314) Lautz TB, Keys LA, Melvin JC, Ito J, Superina RA. Advantages of the meso-Rex bypass compared with portosystemic shunts in the management of extrahepatic portal vein obstruction in children. *J Am Coll Surg* 2013;216:83-89.
  - 315) Mack CL, Zelko FA, Lokar J, Superina R, Alonso EM, Blei AT, et al. Surgically restoring portal blood flow to the liver in children with primary extrahepatic portal vein thrombosis improves fluid neurocognitive ability. *Pediatrics* 2006;117:e405-e412.
  - 316) Shneider B, Emre S, Groszmann R, Karani J, McKiernan P, Sarin S, et al. Expert pediatric opinion on the Report of the Baveno IV



- Consensus Workshop on methodology of diagnosis and therapy in portal hypertension. *Pediatr Transplant* 2006;10:893-907.
- 317) Christison-Lagay ER, Burrows PE, Alomari A, Dubois J, Kozakewich HP, Lane TS, et al. Hepatic hemangiomas: subtype classification and development of a clinical practice algorithm and registry. *J Pediatr Surg* 2007;42:62-68.
  - 318) Mo JQ, Dimashkieh HH, Bove KE. GLUT1 endothelial reactivity distinguishes hepatic infantile hemangioma from congenital hepatic vascular malformation with associated capillary proliferation. *Hum Pathol* 2004;35:200-209.
  - 319) Léauté-Labrèze C, de la Roque ED, Hubiche T, Boralevi F, Thambo JB, Taïeb A. Propranolol for severe hemangiomas of infancy. *N Engl J Med* 2008;358:2649-2651.
  - 320) Léauté-Labrèze C, Hoeger P, Mazereeuw-Hautier J, Guibaud L, Baselga E, Posiunas G, et al. A randomized, controlled trial of oral propranolol in infantile hemangioma. *N Engl J Med* 2015;372:735-746.
  - 321) Zhang DY, Weng SQ, Dong L, Shen XZ, Qu XD. Portal hypertension induced by congenital hepatic arteriportal fistula: report of four clinical cases and review of the literature. *World J Gastroenterol* 2015;21:2229-2235.
  - 322) Maeshima E, Minami Y, Sato M, Matsuda K, Uchiyama K, Goda M, et al. A case of systemic lupus erythematosus with giant hepatic cavernous hemangioma. *Lupus* 2004;13:546-548.
  - 323) Baiges A, Turon F, Simón-Talero M, Tasayco S, Bueno J, Zekrini K, et al. Congenital extrahepatic portosystemic shunts (Abernethy malformation): an international observational study. *HEPATOLOGY* 2020;71:658-669.
  - 324) Rajeswaran S, Johnston A, Green J, Riaz A, Thornburg B, Mouli S, et al. Abernethy malformations: evaluation and management of congenital portosystemic shunts. *J Vasc Interv Radiol* 2020;31:788-794.
  - 325) Lemoine C, Nilsen A, Brandt K, Mohammad S, Melin-Aldana H, Superina R. Liver histopathology in patients with hepatic masses and the abernethy malformation. *J Pediatr Surg* 2019;54:266-271.
  - 326) Luo L, Wu Y, Niu T, Han Y, Feng Y, Ding Q, et al. A multicenter, prospective evaluation of the Chinese Society of Thrombosis and Hemostasis Scoring System for disseminated intravascular coagulation. *Thromb Res* 2019;173:131-140.
  - 327) Poisson J, Plessier A, Kiladjian JJ, Turon F, Cassinat B, Andreoli A, et al. Selective testing for calreticulin gene mutations in patients with splanchnic vein thrombosis: a prospective cohort study. *J Hepatol* 2017;67:501-507.
  - 328) Smalberg JH, Arends LR, Valla DC, Kiladjian JJ, Janssen HL, Leebeek FW. Myeloproliferative neoplasms in Budd-Chiari syndrome and portal vein thrombosis: a meta-analysis. *Blood* 2012;120:4921-4928.
  - 329) Qi X, De Stefano V, Su C, Bai M, Guo X, Fan D. Associations of antiphospholipid antibodies with splanchnic vein thrombosis: a systematic review with meta-analysis. *Medicine (Baltimore)* 2015;94:e496.
  - 330) Hoekstra J, Leebeek FWG, Plessier A, Raffa S, Murad SD, Heller J, et al. Paroxysmal nocturnal hemoglobinuria in Budd-Chiari syndrome: findings from a cohort study. *J Hepatol* 2009;51:696-706.
  - 331) D'Amico M, Sammarco P, Pasta L. Thrombophilic genetic factors PAI-1, MTHFR C677T, V Leiden 506Q, and prothrombin 20210A in noncirrhotic portal vein thrombosis and Budd-Chiari syndrome in a Caucasian population. *Int J Vasc Med* 2013;2013:717480.
  - 332) El Sebay HM, Safan MA, Daoud AA, Tayel SI, Nouh MA, El Shafie S. Association of factor V Leiden, Janus kinase 2, prothrombin, and MTHFR mutations with primary Budd-Chiari syndrome in Egyptian patients. *J Gastroenterol Hepatol* 2016;31:235-240.
  - 333) Qi X, Ren W, De Stefano V, Fan D. Associations of coagulation factor V Leiden and prothrombin G20210A mutations with Budd-Chiari syndrome and portal vein thrombosis: a systematic review and meta-analysis. *Clin Gastroenterol Hepatol* 2014;12:1801-1812.e7.
  - 334) Zhang P, Zhang J, Sun G, Gao X, Wang H, Yan W, et al. Risk of Budd-Chiari syndrome associated with factor V Leiden and G20210A prothrombin mutation: a meta-analysis. *PLoS One* 2014;9:e95719.
  - 335) Saugel B, Lee M, Feichtinger S, Hapfelmeier A, Schmid RM, Siveke JT. Thrombophilic factor analysis in cirrhotic patients with portal vein thrombosis. *J Thromb Thrombolysis* 2015;40:54-60.
  - 336) Qi X, De Stefano V, Wang J, Bai M, Yang Z, Han G, et al. Prevalence of inherited antithrombin, protein C, and protein S deficiencies in portal vein system thrombosis and Budd-Chiari syndrome: a systematic review and meta-analysis of observational studies. *J Gastroenterol Hepatol* 2013;28:432-442.
  - 337) Afredj N, Guessab N, Nani A, Faraoun SA, Ouled Cheikh I, Kerbouche R, et al. Aetiological factors of Budd-Chiari syndrome in Algeria. *World J Hepatol* 2015;7:903-909.
  - 338) Desbois AC, Rautou PE, Biard L, Belmatoug N, Wechsler B, Resche-Rigon M, et al. Behcet's disease in Budd-Chiari syndrome. *Orphanet J Rare Dis* 2014;9:104.
  - 339) Sakr MA, Reda MA, Ebada HE, Abdelmoaty AS, Hefny ZM, Ibrahim ZH, et al. Characteristics and outcome of primary Budd-Chiari syndrome due to Behcet's syndrome. *Clin Res Hepatol Gastroenterol* 2019;44:503-512.
  - 340) Seyahi E, Caglar E, Ugurlu S, Kantarci F, Hamuryudan V, Sonsuz A, et al. An outcome survey of 43 patients with Budd-Chiari syndrome due to Behcet's syndrome followed up at a single, dedicated center. *Semin Arthritis Rheum* 2015;44:602-609.
  - 341) Bureau C, Laurent J, Robic MA, Christol C, Guillaume M, Ruidavets JB, et al. Central obesity is associated with non-cirrhotic portal vein thrombosis. *J Hepatol* 2016;64:427-432.
  - 342) Valla D, Le MG, Poynard T, Zucman N, Rueff B, Benhamou JP. Risk of hepatic vein thrombosis in relation to recent use of oral contraceptives. A case-control study. *Gastroenterology* 1986;90:807-811.
  - 343) Janssen HL, Wijnhoud A, Haagsma EB, van Uum SH, van Nieuwkerk CM, Adang RP, et al. Extrahepatic portal vein thrombosis: aetiology and determinants of survival. *Gut* 2001;49:720-724.
  - 344) Shrestha SM, Okuda K, Uchida T, Maharjan KG, Shrestha S, Joshi BL, et al. Endemicity and clinical picture of liver disease due to obstruction of the hepatic portion of the inferior vena cava in Nepal. *J Gastroenterol Hepatol* 1996;11:170-179.
  - 345) Arachchillage DRJ, Gomez K, Alikhan R, Anderson JAM, Lester W, Laffan M; British Society for Haematology Haemostasis and Thrombosis Taskforce. Addendum to British Society for Haematology Guidelines on Investigation and Management of Antiphospholipid syndrome, 2012 (Br. J. Haematol. 2012; 157: 47-58): use of direct acting oral anticoagulants. *Br J Haematol* 2020;189:212-215.
  - 346) Miyakis S, Lockshin MD, Atsumi T, Branch DW, Brey RL, Cervera R, et al. International consensus statement on an update of the classification criteria for definite antiphospholipid syndrome (APS). *J Thromb Haemost* 2006;4:295-306.